

Management of Penetrating Femoral Artery Injury: Review of 100 Cases in Thi-qar \ Iraq (2013-2020)

Ali Mohsin Obaid, MBChB, FICMS Cardio-Thoracic and Vascular Surgery

Abstract

Background: Extremity arterial injury after penetrating trauma is common in military conflict or urban trauma centers. Most peripheral arterial injuries occur in the femoral and popliteal vessels of lower extremity. Physical examination identifies the majority of vascular injuries and findings are classified either hard signs or soft signs of vascular injury. In general, hard signs constitute indications for operative exploration, whereas soft signs are indications for further testing or observation. Surgical exploration with end to end anastomosis or saphenous vein graft are effective methods in restoring blood flow and limb viability status.

Aim of study: Analysis of 100 cases of penetrating femoral artery injury and determination of ag, gender, mode of presentation, surgical procedures and limb salvage after revascularization.

Patients and Methods: This is a retrospective study on 100 patients had been admitted to the emergency department in Al-Hussain teaching hospital in Thi-qar governorate in Iraq over a period of 7 years from January 2013 to January 2020. All the patients were victims of penetrating injury to the thigh, patients' data were collected from hospital records including age, gender, mode of presentation of vascular injury regarding limb perfusion, preoperative investigations, most common part injured from femoral artery and surgical procedures used for revascularization.

Results:

We reviewed 100 cases of femoral artery injury, 90 patients (90%) were males and 10 patients (10%) females with mean age 33 years .Most commonly superficial femoral artery (SFA) were involved in 78% , common femoral artery 13%, profunda femoris (deep femoral artery) in 9%. Pulse deficit and limb ischemia were the most common clinical findings in seventy five patients (78%), twenty two patients with soft signs (22%) from them (10% with proximity of injury to the major vessels, 8% with hematoma, 4 % with nerve injury). Preoperative imaging were performed in only 22 patients (22%) with subtle clinical findings i.e soft signs while patients with hard signs

of limb ischemia (78%) admitted directly to the operative theatre. End to end anastomosis were performed in 55% , reversed saphenous vein graft in 36% , ligation in only 9 patients (9%) with profunda artery injury, no primary amputation was performed. Limb salvage rate were 98% while secondary amputation was done in only 2 patients due to advanced ischemia during presentation aggravated by long delay between time of injury and surgery.

Conclusions:

There is high rate of limb salvage after femoral artery injury whatever the type of surgical re-vascularization chosen. Pre- operative imaging is unnecessary if there were hard signs for vascular injury.

Keywords: Penetrating injury , femoral artery injury, limb salvage ,amputation.

1. Introduction

Extremity arterial injury after penetrating trauma is common in military conflict or urban trauma centers. Most peripheral arterial injuries occur in the femoral and popliteal vessels of lower extremity¹ . Physical examination identifies the majority of vascular injuries and findings are classified either hard signs or soft signs of vascular injury².

Initial Evaluation & Management:

Unstable patients with isolated penetrating injuries to the extremities should be managed with external compression to control bleeding .Blind clamping for vascular injuries should not be done because of injury risk to adjacent nerves. I.V access with volume loading and prompt triage to the operation room for definitive treatment³. In cases of failure of manual compression or compression dressing, tourniquet can be used but the time should be limited as possible⁴.

Subsequent Management & Definitive Treatment:

In general, hard signs constitute indications for operative exploration, whereas soft signs are indications for further testing or observation¹.

Table 1.1

Hard Signs (Operation Mandatary)	Soft Signs (Further Evaluation)
Pulsatile Hemorrhage	Proximity To Vasculature
Absent Pulses	Significant Hematoma
Acute Ischemia	Nerve Injury
	Thrill Or Bruit
	A-A Index <0.9

A.A index : systolic blood pressure on the injured side compared with that on the uninjured side

In patients with soft signs of arterial injury, the anklebrachial pressure index (ABI) is a highly useful adjunct to the physical examination. The ABI is obtained by placing a standard arm blood pressure cuff on the supine patient proximal to the ankle. The systolic pressure is determined with a Doppler probe at the respective posterior tibial and dorsalis pedis arteries. The ratio of the highest systolic pressure obtained in the affected extremity to the systolic pressure in an unaffected upper extremity is the ABI. It is important to remember that there are several situations in which a vascular injury may not lead to an abnormal ABI. For example, an injury that is considered nonaxial (e.g., an injury to the deep femoral artery in the thigh or the profunda brachii in the arm) may not lower the ABI and thus may be missed. In addition, a lesion that does not disrupt arterial flow (e.g., an intimal flap or a transected artery that is maintained in continuity by connective tissue) may yield a normal ABI. Finally, an AV fistula may be associated with a normal ABI³.

Imaging

Diagnostic Angiography

Traditionally, angiography was the primary imaging modality used to evaluate patients suspected of sustaining an arterial injury from penetrating lower extremity trauma. Limitations of angiography include the risk of associated complications, including damage to the access vessel and hematoma formation, as well as the fact that it is resource intensive and may require specialized personnel. Overall, intra-arterial contrast injection has a complication rate of 1% to 4%^{1,3}.

CT angiography

CTA is demonstrated in retrospective and prospective studies to have a sensitivity and specificity rate that is equivalent to conventional angiography. CTA is readily available and noninvasive and

is associated with lower overall costs. In patients with penetrating lower extremity injury who require imaging to assess for arterial injury, CTA may be used as the primary imaging modality^{1,3}. CTA has the advantage of using intravenous contrast only ,being readily available & cost effective. Limitations may occur when metallic fragments or bullets causes CT artifacts, contrast load needed may be detrimental in patient with preexisting renal insufficiency or concurrent renal injury⁴.

Duplex ultrasonography

Numerous clinical studies have documented the excellent accuracy of duplex ultrasonography in assessing arterial injuries. While sensitivity has ranged from 50% to 100%, specificity and accuracy have consistently exceeded 95%. Disadvantages of this diagnostic approach include the initial cost of the equipment, need for 24-hour availability of a registered vascular technologist or experienced vascular surgeon trained in duplex⁴.

Surgical Treatment

The injured vessel segment is excised, external fixation of the femur typically is performed, followed by end-to-end or RSVG of the injured SFA segment. Close monitoring for calf compartment syndrome is mandatory¹.

2. Aim of study

Analysis of 100 cases of penetrating femoral artery injury and determination of age ,gender ,mode of presentation, surgical procedures and limb salvage after revascularization.

3. Patients & Methods

This is a retrospective study which was conducted on 100 patients admitted to the emergency department in Al-Hussain teaching hospital in Thi-Qar governorate in Iraq over a period of 7 years from January 2013 to January 2020 . ALL the patients were victims of penetrating injury to the the thigh, patients data were collected from hospital records including age, gender ,hemodynamic status, mode of presentation of vascular injury regarding limb perfusion , preoperative investigations, intraoperative findings regarding which part of femoral artery was injured and surgical procedures used for revascularization.

4.Results

In our study we retrospectively re-viewed the records of 100 patients admitted with penetrating injuries to the thigh in Al-hussein teaching hospital in Thi-qar governorate . we found that the age

distribution of victims were from 10 to 60 years with mean age 33 years . Ninety percent (90%) males and (10 %) were females.

Table 2.1 age distribution

Age	Number Of Patients	Percentage%
10- Years	9	9%
20- Years	28	28%
30- Years	40	40%
40- Years	18	18%
50-60 Years	5	5%

Table 2.2 (Sex of patients)

Sex	Number Of Patients	Percentage %
Male	90	90%
Female	10	10%

Most commonly injured part from the femoral artery was the superficial femoral artery found in 78% of patients, common femoral artery in 13 % , profunda femoris artery in 9% of patients.

Table 2.3 (femoral artery most injured part)

Injured Part	Number Of Patients	Percentage %
Superficial Femoral	78	78%
Common Femoral	13	13%
Profunda Femoris	9	9%

Mode of presentation was different regarding limb perfusion status and presence of limb ischemia, there were 78% patients presented with limb ischemia with absence of pulses while only 22% presented with soft signs (10% proximity to the major vessels, 8% with significant hematoma & 4% with nerve injury).

Table 2.4 (Mode of Presentation)

Clinical Finding	Number Of Patients	Percentage
Absent Pulse	78	78%

Proximity To Major Vessels	10	10%
Hematoma	8	8%
Nerve Injury	4	4%
Total	100	100%

Preoperative investigations to define arterial injury were performed only in patients with subtle clinical signs of vascular injury i.e soft signs (22%) where CT angiography was the diagnostic tool of choice, while patients with hard signs (78%) were admitted directly to the operation room.

Different surgical procedures were performed regarding arterial repair. Primary anastomosis of arterial injury were performed in majority of cases (55%), interposition reversed saphenous vein graft in (36%) and ligation in 9 patients (9%) in patients with isolated profunda artery injury. No primary amputation was performed.

Table 2.5 (Type of Surgery)

Primary Arterial Repair	55%
Reversed Saphenous Vein Graft	36%
Ligation	9%
Total	100%

Limb salvage in form of viability post intervention were attended in 98 patients (98%) , while secondary amputations were performed in only 2 patients (2%) due to advanced ischemia during presentation aggravated by long delay between time of injury and surgery.

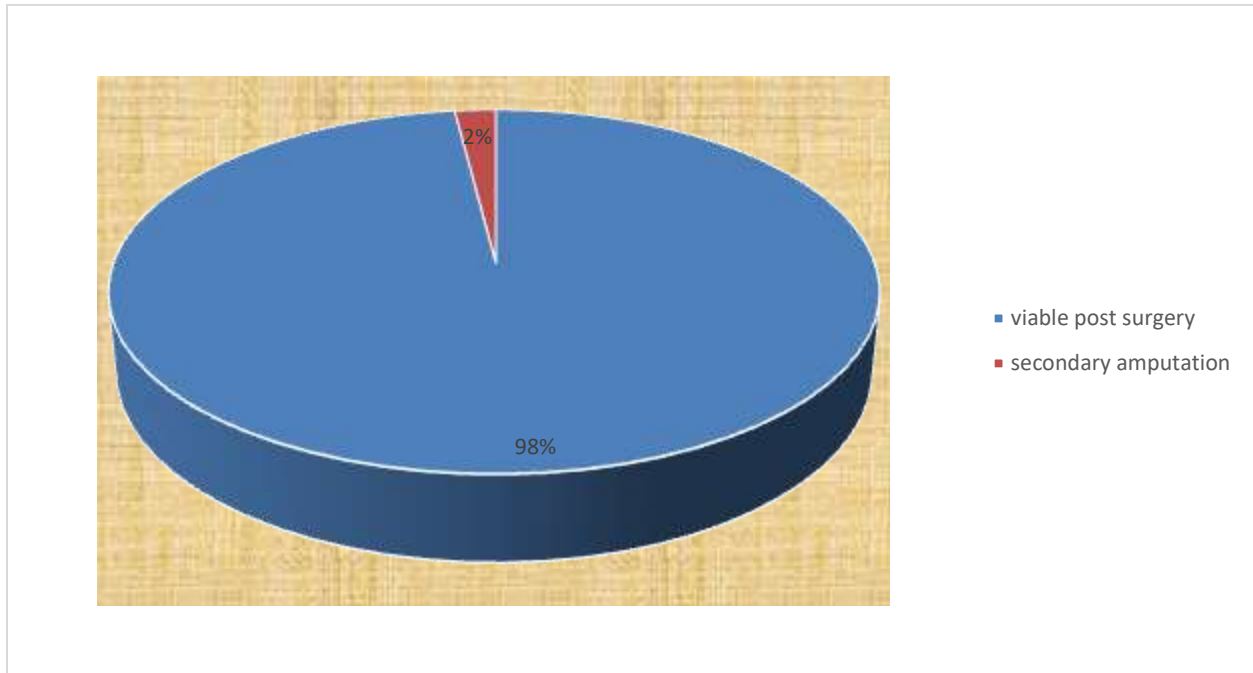


Figure 1.1 (Limb Salvage Rate)

5.Discussion

In our study we reviewed 100 cases of penetrating femoral artery injury over a period of 7 years from 2013 to 2020, we found that the mean age of patients was 33 years from them 90 were males (90%) and 10 patients were females (10%). The high incidence of injuries in young males may be due to their involvement in most of criminal accidents and fight injuries more than females, these findings were similar to a study made by Rayamajhi and colleagues in 2019⁵ on 158 patients, he found that the number of males were 144 (91%) and number of females were only 14 (9%) with mean age 28 years. Our findings were also similar to a study made by Wolosker⁶ and colleagues in 1996 on 74 patients, he found that the mean age was 24 years old with seventy one patients were males (96%) and three females (4%).

In our study we found that the most injured part of the femoral artery was the superficial femoral artery (SFA), there were 78 patients with SFA injury (78%), 13 patients with common femoral artery injury (13%) and only 9 patients with injury to profunda femoris artery (9%). The high incidence of SFA trauma may be due to long course of this artery from below the bifurcation of common femoral artery in the upper thigh to the adductor hiatus where it becomes the popliteal artery. The same results were found by Rayamajhi and colleagues study as they found that the superficial femoral artery was most commonly injured in (87%) while in Wolosker and colleagues study SFA was impaired in (77%) of cases.

Most frequent clinical finding was pulse absent in (78%) of patients, while in Wolosker & colleagues study pulse absent was found in (62.5%). Preoperative imaging was not routinely performed and most patients with clinical evidence of limb ischemia were admitted directly to the operation room (78%) while CT angiography was performed in only 22% of patients with soft signs ,no preoperative arteriography performed to any of our patients as it was not feasible in our hospital at that time. Same results were found by Wolosker were only five patients underwent preoperative angiography due to multiple penetrating trauma or asymptomatic penetrating wound along a vessel passage.

In a study performed by Degiannis⁷ and colleagues in 1995 on 106 patients with penetrating injuries to the femoral artery, they found that preoperative angiography is unnecessary in patients with hard signs of vascular injury.

In our center study we found that the main surgical procedure performed was end to end anastomosis of the injured SFA parts after debridement and mobilization of both ends of the artery which was feasible in 55% of cases ,reversed saphenous vein graft anastomosis was done in 36% of cases, no prosthetic graft had been used while ligation was the surgical procedure of choice in only 9% of patients who had documented injury to profunda femoris artery and no primary amputation was recorded. The same results were found in Rayamajhi and collaegues⁵ as they found that most common surgical procedure was primary repair in eighty-one (51%) patients , fifty-three (33%) patients had a vein interposition graft, 16 patients (10%) had a prosthetic graft and there were 4 (2.5%) primary amputations may be due to severe associated injuries or the irreversible ischemia at time of presentation, in our records no primary amputation was done at the initial surgical intervention .In Wolosker and colleagues study they found that 64 patients (86.5%) had a venous graft this is may be due to severe traumatic transection of femoral artery with segment loss and also he found that no primary amputation was performed as we found in our study.

Regarding limb salvage we found that 98% of patients had viable limb while secondary amputation was the choice in only 2 patients. The same results were found by Rayamajhi and colleagues as there were 90% of patients with limb preservation post re-vascularization and secondary amputation in 10 patients (6.5%).The lower rate of amputation in our study may be due to less severe type of trauma presented and recorded in our hospital records in form of associated injuries and also reflect the early re-vascularization of the injured limbs. In Wolosker study the limb salvage was achieved in 72 patients (97.3%) while amputation was done in 2 patients due to long delay before re-vascularization and severe associated soft tissue injuries.

6.Conclusions

There is high rate of limb salvage after femoral artery injury whatever the type of re-vascularization chosen. Pre- operative imaging is unnecessary if there were hard signs for vascular injury.

7.References

- 1.Nicole Fox ,MD, MPH, Ravi R. Rajani, MD, Faran Bokhari,MD.MBA,William C.Chiu,MD,Andrew Kerwin,MD,Mark J. Seamon,MD, David Skarupa, MD, and Eric Frykberg, MD. Evaluation and management of penetrating lower extremity arterial trauma: An Eastern association for the surgery.
2. Clay Cothren Burlew and Ernest E. Moore : Trauma. In F. Charles Brunicaudi, MD, FACS, Dana K. Anderson MD,FACS, Timothy R. Blliar, MD, FACS, Schwartz `s Principles of Surgery, 11th edition, Mc-Graw Hill Education ,2019 : page 205.
3. Todd R. Vogel, MD, MPH, FACS, Paul L. O'Donnell, DO, and Gregory J. Jurkovich, MD, FACS, Injuries to the peripheral blood vessels, ACS Surgery Principles and Practice ,7th edition, 2012 Decker Intellectual Properties,p 2035.
4. Frykberg ER, Dennis JW, Bishop K, et al. The reliability of physical examination in the evaluation of penetrating extremity trauma : results at one year .J Trauma 1991,31:502-511.
5. Shreya Rayamajhi , Nivashini Murugan, Andrew Nicol, Sorin Edu, Juan Klopper , Nadraj Naidoo , Pradeep Navsaria , Penetrating femoral artery injuries: an urban trauma center experience, Eur J Trauma Emerg Surg . 2019 Oct;45(5):909-917.
6. N Wolosker 1, A Guadêncio, S Kuzniec, R A Rosoky, C Kalume, C A Neves, R Aun, B Langer, Surgical treatment of noniatrogenic trauma of the femoral arteries, Sao Paulo Med J. 1996 Jan-Feb;114(1):1079-82.
7. E Degiannis 1, R D Levy, G C Velmahos, T Potokar, R Saadia, Penetrating injuries of the femoral artery, Br J Surg. 1995 Apr;82(4):492-5.