

# Use of Fiberoptic Bronchoscopy for Removal of Inhaled Endobronchial Headscarf Pins in Adults

*Alaa Kassar Salih. MBCHB; FIBMS (CTV)*

Department of Surgery, Vascular surgery unit, College of Medicine, Al-Nahrain University, Al-Kadhimiya Teaching Hospital, Baghdad, Iraq

## **Abstract**

**Background:** Foreign body (FB) aspiration is a worldwide health problem which can result in a life threatening complications. It most commonly occurs among children younger than 4 years of age, yet inhalation of sharp foreign bodies are seen more commonly in adults.

Headscarf pin inhalation is a common and unique form of foreign body inhalation among young Moslem women wearing a hijab. Standard flexible bronchoscopy (FOB) is used increasingly in the treatment of tracheobronchial foreign body inhalation in adults and older children, especially in the removal of inhaled foreign bodies which have entered into the peripheral bronchi.

**Objectives:** The aim of this study is to investigate the success rate of fiberoptic

bronchoscopy (FOB) in endobronchial headscarf pin removal, how to minimize complications, and recommend techniques to facilitate the application.

**Patients and methods:** Patients with the diagnosis of headscarf pin inhalation admitted to Al-Kadhimiya teaching hospital, department of cardiothoracic and vascular surgery from January 2013 to September 2014 were included in the study. Standard FOB procedure using an oral approach in recumbent position under local anesthesia and conscious sedation was performed as the primary tool for retrieval, the process was not repeated when the foreign body could not be removed. In these cases, the foreign body was removed by rigid bronchoscopy under general anesthesia.

### **Results:**

A total of 19 cases were admitted during the study period. The mean age of the sample was 23.16 years (13-45 years). Twelve patients presented with cough (63.16%) while only one patient had hemoptysis (5.26%), four.

patients had chest pain (21.05%) and two patients had dyspnea(10.53%). Retrieval of

the inhaled pin by fiberoptic bronchoscopy was successful in 17 patients (89.47%). In one patient (5.26%) FOB was not successful so the FB was removed by using rigid bronchoscope under general anesthesia while thoracotomy was performed in one patient (5.26%) after unsuccessful attempts of both FOB and rigid bronchoscope.

### **Conclusion:**

Sharp pin inhalation is a serious hazard and can have lethal outcome. It is a common form of tracheobronchial FB inhalation among young Muslim females who have the habit of holding the pin between their lips or teeth while doing or undoing their headscarves. This results in accidental sudden inhalation while talking or laughing.

Flexible FOB under conscious sedation and local anesthesia can be a useful first- step tool in retrieving inhaled headscarf pins, especially in distal airways, in adolescents and adults in the hands of an experienced bronchoscopist and a well-equipped bronchoscopy unit.

### **Introduction**

Accidental foreign body inhalation is a relatively common occurrence in the pediatric population <sup>[1, 2]</sup> and may lead to asphyxiation and death especially among those younger than 4 years of age <sup>[3]</sup>. Foreign body inhalation is uncommon in psychiatric disorders, and those using oral prostheses and sedatives ,an increased risk of foreign body inhalation exists <sup>[5, 6]</sup>.

adults <sup>[4]</sup>. In adults, foreign body inhalation does not cause asphyxia, although comorbid diseases may occur in older population. In adults with corrupted oropharyngeal reflexes, neurological and

A unique form of foreign body inhalation is recently described among young Muslim girls who wear headscarves (Hijab) <sup>[7-11]</sup>. A sharp pin (headscarf or turban pin) is

commonly used to hold the headscarf in place. The pin is about 4 cm in length with a smooth rounded pearl-like head (fig.1). It is a common practice to hold the pin between the teeth while both hands are used to adjust the head scarf. Inhalation usually happens during talking or laughing while the head is tilted backward.

Flexible fiberoptic bronchoscopy (FOB) is commonly used to diagnose and retrieve tracheobronchial foreign bodies in adults with a high success rate [12, 13]. However, in cases of headscarf pin

inhalation, rigid bronchoscopy (RB) is considered to be the standard procedure for extraction and FOB was rarely used [8, 9]. It has recently been reported that fiberoptic bronchoscopy (FOB) is also effective and reliable [14-16].

In the present study, we investigated the effectiveness and safety of FOB under conscious sedation and local anesthesia as the initial procedure for extraction of aspirated endobronchial headscarf pins in Iraq, Baghdad city.

### **Material and Methods**

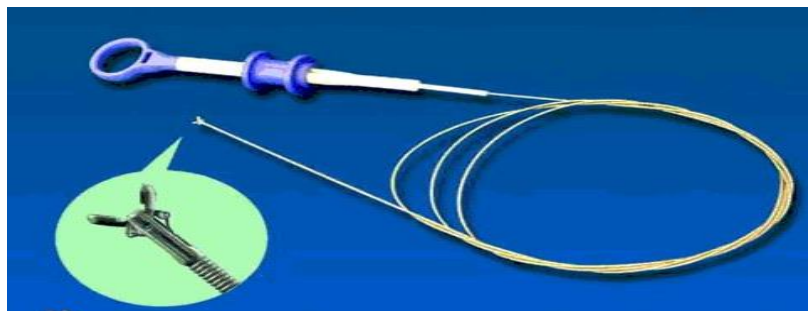
All patients who were referred to Al-Kadhimiya teaching hospital, department of cardiothoracic and vascular surgery with the diagnosis of headscarf pin aspiration were included in the study (19 patients). The study period was from January 2013 to September 2014. Diagnosis of headscarf pin aspiration was established by typical history and posterior-anterior and lateral chest radiography (fig3). Standard FOB procedure was performed in the endoscopy unit on the same day. A flexible Storz video bronchoscope was used. Sedation was achieved with intravenous midazolam under cardiopulmonary monitoring. Topical

anesthesia was performed with 10% lidocaine spray for the pharynx and 2% lidocaine for the larynx and the tracheobronchial tree. The bronchoscope was passed through the mouth. The pin was removed by using biopsy forceps. Once a firm hold of the pin was secured, the grasping instrument was withdrawn to the tip of the bronchoscope, and then, the bronchoscope and the grasping instrument were both slowly withdrawn under direct vision. After retrieval of the pin, the bronchoscope was passed again to inspect any possible post retrieval damage to the larynx, vocal cords or the tracheobronchial tree.

**Fig.1.** Headscarf pins with smooth rounded pearl-like heads

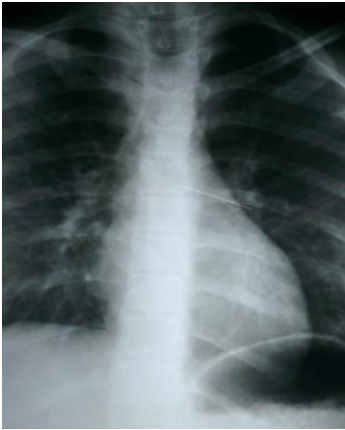

**Fig.2** Biopsy force

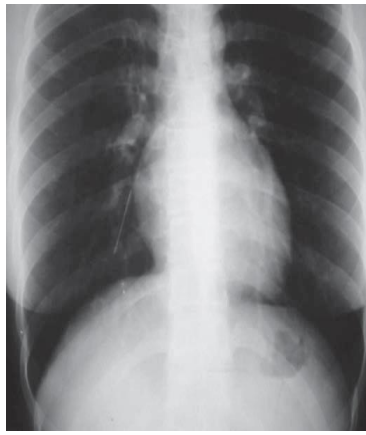


**Fig.3** Chest radiograph examination:

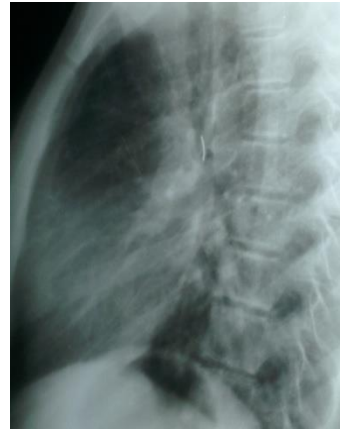- A. Posteroanterior view showing pin in the left main bronchus
- B. Posteroanterior view showing pin in the right lower lobe bronchus
- C. Lateral view showing pin in the left main bronchus



A.



B.



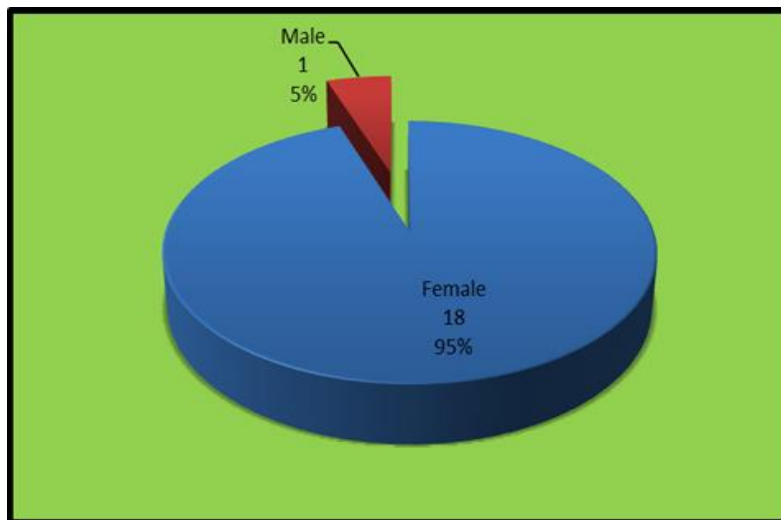
C.

**Results**

**Table.1: Age distribution**

<b><u>Character</u></b>	<b><u>Value</u></b>
<b>Mean age</b>	<b>23.16</b>
<b>Age range</b>	<b>(13-45) years</b>

**Figure.4: Sex of patients**



**Table.2:History of inhalation**

<u>History of inhalation</u>	<u>No.</u>	<u>Percentage</u>
<b>Total</b>	<b>19</b>	<b>19%</b>

**Table.3: Time elapsed between inhalation and FOB**

<b>Time elapsed between inhalation and FOB</b>	<b>(&lt;24hr-4days) (median = 1 day)</b>
--	--

**Table.4: Location of foreign body in the tracheobronchial tree**

<b>Location of foreign body</b>	<b>No.</b>	<b>Percentage</b>
<b>Left main bronchus</b>	<b>10</b>	<b>52.63</b>
<b>Left lower lobe bronchus</b>	<b>8</b>	<b>42.11</b>
<b>Right lower lobe bronchus</b>	<b>1</b>	<b>5.26</b>

**Table.5: Type of procedure**

<b>Type of procedure</b>	<b>No.</b>	<b>Percentage</b>
<b>Fiberoptic Bronchoscopy</b>	<b>17</b>	<b>89.47</b>
<b>Rigid Bronchoscopy</b>	<b>1</b>	<b>5.26</b>
<b>Thoracotomy performed</b>	<b>1</b>	<b>5.26</b>

A total of 19 cases were admitted to the hospital with the diagnosis of headscarf pin inhalation during the study. All patients were previously healthy with a mean age of 23.16 years (range 13–45). The time interval between aspiration and admission to our unit was between less than 24hs and 4 days (median=1 day).

The pin was found in the left main bronchus in 10 cases (52.63%), in the left lower lobe bronchus in 8 cases (42.11%), and in the right lower lobe bronchus in 1 case (5.26%).

All inhaled pins in the tracheobronchial tree were found with the pearl head down and the sharp end up and embedded in the mucosa.

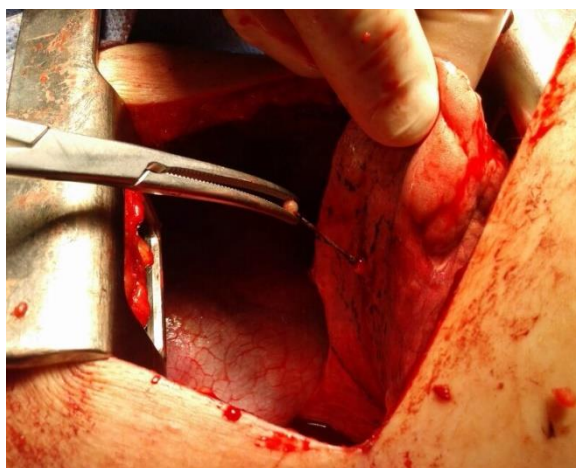
One patient was male (5%) and 18 patients (95%) were females.

The pin was successfully retrieved during the first attempt of FOB in 17/19 cases (89.47%).

FOB was not successful in retrieving the pin in two cases. In one case, the sharp end of the pin was found to be firmly embedded in the mucosa. Several attempts to dislodge it were unsuccessful and the pin was successfully retrieved by rigid bronchoscope

RB under general anesthesia. The patients were discharged

the following day. In another patient the aspirated pin was found in the posterior basal segment of the left lower lobe. The sharp end of the pin was barely visible by FOB as it was covered by granulation tissue. Retrieval attempts were not successful using FOB and RB under general anesthesia and fluoroscopy guidance. The pin was then removed by thoracotomy.



**Fig.5** Thoracotomy performed for retrieval of pin in the posterior basal segment of the left lower lobe.

## Discussion

Traditionally, RB has been the procedure of choice for the removal of foreign bodies in children [12]. FOB is used increasingly in the treatment of the FBA in adults [17, 18].

In most reported studies, sharp foreign bodies such as pins were removed either by using RB alone or RB and FOB together [19], but in some studies, FOB alone was used for their removal with success rate varies between

86 and 100% [14,20].RB should be preferred in small children or when the foreign body is large enough to obstruct a main airway [20,21]. This study is to evaluate the utility of FOB as a primary tool for removal of inhaled headscarf pins. We treated 19 cases of head scarf pin aspiration using FOB with a success rate of 89.47%.

In one case FOB was not successful as the pin was firmly embedded in the

bronchial mucosa therefore RB under general anesthesia was required to remove it. Another one case required thoracotomy because the pin was lodged distally in the bronchial tree & FOB failed to remove it. Also using FOB as a primary tool for removal of inhaled headscarf pins helped to localize the site of pin even if failing to remove it, which facilitate removal by RB. In this study, 1 patient required thoracotomy, indicating a thoracotomy rate of (5.26%). The thoracotomy rate in our study is similar to those previously reported (1.6–18%), [7, 8, 11]. We believe that the need for thoracotomy is not necessarily related to the use of FOB as a tool for retrieval, but it may be related to the peripheral settlement of the pin, delayed time of presentation after inhalation, and the formation of granulation tissue around the inhaled pin.

As in previous reports, all aspirated pins were found head down because girls usually hold the pearl head of the pin in the mouth while they are fixing the headscarf, and all patients in our study were of a young age group, with a mean age of (23.16) years, which is similar to previous reports [7–11].

In this study the majority of pins were located in the left bronchial tree which is different from the reports in other studies [7, 8, 11].

Headscarf pin aspiration appears to be an accidental problem due to the habit of placing the pin in the mouth while fixing the headscarf hence the majority of patients (95%) were females only one patient (5%)

was young male who used to place the pin in his mouth during his work in hand made hijab sewing local factory in Al-Kadhimiya city, Baghdad. In this study, there were no predisposing risk factors for aspiration. All patients were healthy and had normal medical and neurological examination.

A potential complication of the approach with FOB under conscious sedation and local anesthesia is the risk of damage to the larynx or tracheobronchial tree during retrieval of inhaled pins. In this study, we did not encounter such complications. Another potential complication is the risk of losing the pin in the throat. The pin is then quickly swallowed and settles in the stomach. In this study, we did not encounter such complications. FBA in adults is a rare problem. The largest series reported 1–3 cases per year [4, 6, 16, 17, 20]. In most of the cases, the aspirated material was organic, either bone fragments or vegetable material. In this study, we encountered more than 5 cases annually of inhaled headscarf pins in a relatively small population area. This makes headscarf pin inhalation the most common form of FBA in young healthy Moslem Iraqi women.

This problem can be prevented by increasing public awareness, including avoidance of holding the pin in the mouth while fixing the headscarf or wearing a type of headscarf that does not need a pin for fixation. However, if pin inhalation occurs, early presentation to hospital is advisable as it might make retrieval of the pin easier.



## References

- 1- Swanson KL, Prakash UBS, Midthun DE, *et al.* Flexible bronchoscopic management of airway foreign bodies in children. *Chest* 2002; 121: 1695-1700.
- 2- Tan HK, Tan SS. Inhaled foreign bodies in children anesthetic considerations. *Singapore Med J* 2000; 41: 506-510.
- 3- Mantor PC, Tuggle DW, Tunell WP. An appropriate negative bronchoscopy rate in suspected foreign body aspiration. *Am J Surg* 1989; 158: 622-624.
- 4- Baharloo F, Veyckemans F, Francis C, Bieltlot MP, Rodenstein DO: Tracheobronchial foreign bodies: presentation and management in children and adults. *Chest* 1999; 115:1357–1362.
- 5- Tariq SM, George J, Srinivasan S. Inhaled foreign bodies in adolescents and adults. *Monaldi Arch Chest Dis* 2005; 63:193-8.
- 6- Limper AH, Prakash UB. Tracheobronchial foreign bodies in adults. *Ann Intern Med* 1990; 15:604-9.
- 7- Ucan ES, Tahaoglu K, Mogolkoc N, Dereli S, Basozdemir N, Basok O, Turktas H, Akkoclu A, Ates M: Turban pin aspiration syndrome: a new form of foreign body aspiration. *Respir Med* 1996; 90:427–428.
- 8- Kaptanoglu M, Dogan K, Onen A, Kunt N: Turban pin aspiration; a potential risk for young Islamic girls. *Int J Pediatr Otorhinolaryngol* 1999; 48:131–135.
- 9- Murthy PSN, Ingle VS, George E, Ramakrishna S, Shah FA: Sharp foreign bodies in the tracheobronchial tree. *Am J Otolaryngol* 2001; 22:154–156.
- 10- Shabb B, Taha AM, Hamada F, Kanj N: Straight pin aspiration in young women. *J Trauma* 1996; 40:827–828.
- 11- Gokirmak M, Hasanoglu HC, Koksall N, Yildirim Z, Hacievliyagil SS, Soysal O: Retrieving aspirated pins by flexible bronchoscopy. *J Bronchol* 2002; 9:10–14.
- 12- Martinot A, Closset M, Marquette CH, Hue V, Deschildre A, Ramon P, Remi J, Leclerc F: Indications for flexible versus rigid bronchoscopy in children

with suspected foreign body aspiration. *Am J Respir Crit Care Med* 1997; 155:1676–1679.

- 13- Swanson KL, Prakash UB, Midthun DE, Edell ES, Utz JP, McDougall JC, Brutinel WM: Flexible bronchoscopic management of airway foreign bodies in children. *Chest* 2002; 121:1695–1700.
- 14- Rafanan AL, Mehta AC. Adult airway foreign body removal. What's new? *Clin Chest Med* 2001; 22:319-30.
- 15- Donado Una JR, de Miguel Poch E, Casado Lopez ME, et al. Fiberoptic optic bronchoscopy in extraction of tracheo-bronchial foreign bodies in adults. *Arch Bronconeumol* 1998; 34(2): 76–81.
- 16- Lan RS, Lee CH, Chiang YC et al. Use of fiberoptic bronchoscopy to retrieve bronchial foreign bodies in adults. *Am Rev Respir Dis* 1989; 140:1734-7.
- 17- Chen W, Cheng D, Ji C: The diagnostic and therapeutic value of flexible bronchoscopy in foreign-body aspiration misdiagnosed as other respiratory diseases. *Hua Xi Yi Ke Da Xue Xue Bao* 1999; 30: 327–328.
- 18- Gerritsen J: Flexible bronchoscopy in children: an open airway. *Eur Respir J* 2003; 22:576–577.
- 19- Ruegamer JL, Perkins JA: Combined rigid and flexible endoscopic removal of a BB foreign body from a peripheral bronchus. *Int J Pediatr Otorhinolaryngol* 1999; 47: 77–80.
- 20- Debeljak A, Sorli J, Music E, Kecelj P: Bronchoscopic removal of foreign bodies in adults: experience with 62 patients from 1974–1998. *Eur Respir J* 1999; 14: 792–795.
- 21- Dikensoy O, Usalan C, Filiz A: Foreign body aspiration: clinical utility of flexible bronchoscopy. *Postgrad Med J* 2002; 78: 399–403.