

Inferior Thyroid Artery Ligation in Thyroid Surgery

Dr. Haider Hadi Manshad

General surgeon / M.B.Ch.B D.G.S / Thi-Qar Health Directorate / Al-Hussein Teaching hospital

Abstract

Context: Thyroidectomy is a major as well as common surgery usually performed by endocrine or general surgeon. The postoperative complications, although rare in experienced hands, have severe implications on the patients.

Aim: - this study issued in Iraqi hospitals aimed to assess the effects and outcomes that result following ligation of the inferior thyroid artery during the procedure of thyroidectomy versus those which may follow thy roidectomy without ligation of this artery especially in the immediate postoperative period.

Patients & Methods: in this study 30 patients presented with goiter underwent different operations done by different surgeons from Jan. 2016 to Jan. 2017. The evaluation included the intraoperative maneuvers concerning ligation of the inferior thyroid artery during thyroidectomy whether ligation is done in continuity or by ligation-division or as temporary ligation & the effect and outcome of this step was studied in relation to the immediate postoperative complications in comparison to those without ligation of the inferior thyroid artery.

Results: the immediate postoperative complications and outcome following thyroidectomy with or without ligation of the inferior thyroid artery are relatively similar and show no significant difference.

Conclusion: the study results showed that no statistically significant difference was reported following thyroidectomy with ligation of the inferior thyroid artery versus those without ligation of this artery. Actually ligation of this artery has no effect on the outcome and subsequent postoperative complications .

Keywords: Thyroidectomy, Thyroid Artery, Ligation, Thyroid Surgery.

Introduction:

Thyroid gland begins to develop during the 3rd week as an endodermal thickening in the midline of the floor of the pharynx between the tuberculum impar and the copula ⁽¹⁾, so thyroid gland develops from the midline bud of the pharynx (thyroglossal duct) which descends from the foramen cecum at the base of the tongue to the isthmus of the thyroid ⁽²⁾. Later this thickening becomes a diverticulum that grows inferiorly into the underlying mesenchyme and is called thyroglossal duct ⁽¹⁾. This duct elongates and at its distal end bilobed. The bilobed terminal swellings expand to form the thyroid gland which now migrates inferiorly in the neck. The thyroid gland is derived from the word *thyroides* which means shield-shaped ⁽⁴⁾. It is brownish – red highly vascular endocrine gland and it usually weighs 20-25 g in the adult , it is slightly heavier in women and enlarges physiologically at puberty and during menstruation and pregnancy⁽⁵⁾. Thyroid gland consists of two lobes connected across the midline by an isthmus , each lobe extends superiorly up to the oblique line of the thyroid cartilage and inferiorly to the 4th or 5th tracheal rings. The isthmus extends across the midline in front of the 2th, 3th and 4th tracheal rings ⁽¹⁾. The normal thyroid gland is impalpable ⁽²⁾. Arterial blood supply is very rich and extensive anastomoses occur between the main

thyroid arteries and branches of tracheal and oesophageal arteries ⁽²⁾. The arteries to the thyroid gland are the superior thyroid artery , a branch of the external carotid artery, descends to the upper pole of each lobe accompanied by the external laryngeal nerve which supplies the cricothyroid muscle. Inferior thyroid artery, a branch of the thyrocervical trunk of subclavian artery. It ascends behind the thyroid gland to the level of the cricoid cartilage, then it runs medially and downwards to reach the posterior border of the gland ⁽¹⁾. The recurrent laryngeal nerve comes into direct relationship with the terminal branches of the inferior thyroid artery being posterior, but may pass anterior to or between its branches ⁽³⁾. Thyroid ima artery, if presents, may arise from the brachiocephalic artery or the arch of the aorta. It ascends in front of the trachea to the isthmus. Veins from thyroid gland are the superior thyroid vein which drains into the internal jugular vein ,the middle thyroid vein which drains into the internal jugular vein and inferior thyroid vein which anastomoses with the other one as they descend in front of the trachea to drain into the left brachiocephalic vein in the thorax⁽¹⁾ .

Recurrent laryngeal nerve (RLN) is the main sensory and motor nerve of the larynx ⁽⁶⁾ . In general, right recurrent laryngeal nerve arises from the vagus

nerve as the later crosses the first part of the subclavian artery. It hooks backwards and upwards behind the artery and ascends in the groove between trachea and oesophagus. The left recurrent laryngeal nerve arises from the vagus as this crosses the arch of the aorta in the thorax. It hooks around beneath the arch behind the legamentum arteriosum and ascends into the neck in the groove between the trachea and oesophagus ⁽¹⁾. The course of the recurrent laryngeal nerve is arbitrary divided into three parts: in the lower third it passes obliquely upwards and forwards and is covered by a thin fascia which encloses the trachea and inferior thyroid vein. In the middle third the nerve runs parallel and closely related to the trachea. It runs medial, within or lateral to the facial condensation termed "suspensory ligament of Berry". In the upper third it runs constantly medial to the suspensory ligament and arches gently backward to enter the larynx behind the inferior cornu of the thyroid cartilage which provides a very valuable landmark of the nerve, however, this anatomical disposition is not constant ^(7,8). Parathyroid glands are important related structures to the thyroid and deserve mention here since they are vulnerable to injury during thyroidectomy. They are ovoid bodies, soft, mobile, yellowish- brown in color, four in number, and about 0.5 cm in size ⁽²⁾. Total weight of the glands ranges from 90-140 mg. in 80%

of cases the upper glands are fixed in position and related to the posterior aspect of the upper two thirds of thyroid lobes. The inferior glands are of fixed position in only 60% of cases where the common site is the area intersection of inferior thyroid artery and RLN. Each gland is supplied by a branch from the inf.thyroid artery that enters at the hilum, sometimes the superior gland is supplied by the supthyroid artery ⁽³⁾. Nevertheless, the blood supply of parathyroid may be damaged during ligation of the inf.thyroid artery ⁽⁹⁾.

Goiter: Latine gutter= the throat, it is used to describe a generalized enlargement of the thyroid. A discrete swellings or thyroid nodules are common and more frequent in women than men, a discrete swelling in an impalpable evidence of generalized mild abnormality in the form of generalized mild nodularity is known as dominant. In general, about 70% of discrete thyroid nodules are clinically isolated (solitary) and about 30% are dominant ⁽²⁾. Generally goiter is a dramatic enlargement of the thyroid gland due to excess production of thyroid hormones or due to increased growth of thyroid gland causing compression of important neck structure or simply appearing as a neck mass, sometimes goiters may acutely grow into the chest (retrosternal) where they cause some obstructive symptoms ⁽¹⁰⁾. In fact, endemic areas in the world are in the mountainous ranges such as

the Alps, the Andes, the Himalayas and the Rocky mountains ⁽²⁾. In Iraq, goiter is endemic disease especially in the north and middle zones ⁽¹¹⁾. In general, Goitre can be classified into:

1- Simple goiter: results from stimulation of thyroid gland by elevated levels of TSH as a result of an absolute or relative decrease in the circulating thyroid hormones. The most important factor in endemic goiter is dietary deficiency of iodine but defective hormone synthesis probable accounts for many sporadic goiters ^(2,3).

- a. Diffuse hyperplastic goiter (physiological).
- b. Multinodular goiter (simple).
- c. Simple colloid goiter (hyperinvolution of diffuse hyperplastic goiter).

2- Toxic goiter: due to excess production of thyroid hormones.

- a- Diffuse toxic goiter (Graves ' disease or primary thyrotoxicosis).
- b- Toxic nodular goiter (Plummer's disease or secondary thyrotoxicosis).
- c- Toxic nodules (solitary nodule) ⁽³⁾.

3- Inflammatory goiter ⁽³⁾:

- a- Autoimmune goiter as Hashimotos thyroiditis.
- b- Granulomatous goiter (subacute thyroiditis) as De Quervains disease.
- c- Acute bacterial thyroiditis.

d- Chronic thyroiditis as TB or Syphilis.

e- Fibrosing thyroiditis as Riedels thyroiditis.

4-Neoplastic goiter ⁽²⁾:

- a- Benign as Follicular adenoma.
- b- Malignant either primary or secondary.

The primary malignant tumour includes:

- Papillary carcinoma.
- Follicular carcinoma.
- Medullary carcinoma.
- Anaplastic carcinoma.
- Lymphoma.

In practice, surgery is the treatment of choice for majority of the pathology ⁽¹²⁾. Thyroid surgery was hazardous until the mid-19th century when advances in general anesthesia, antiseptic and hemostasis enabled surgeons to perform thyroid surgery with significantly reduced mortality ⁽⁴⁾. The first thyroidectomy was performed by Albucasis (AD 936-1013), the Moorish physician surgeon of Andalusia ⁽¹³⁾. Subtotal thyroidectomy is the standard procedure for goiters, wherever the goiter size a remnant of 3-4g is retained on each side (total 6-8g.), and this remnant measures 5x1 cm ⁽¹⁴⁾.

However, the extent of resection, though, depends on the size of the gland, the age of the patient, the experience of the surgeon, the need to minimize the risk of recurrent toxicity (in toxic goiter), and wish to avoid

postoperative thyroid replacement ⁽²⁾. Subtotal thyroidectomy implies removal of the greater part of the enlarged gland, the operation being a bilateral one, leaving an equal and symmetrical amount of gland tissue on each side ⁽¹⁵⁾.

Each thyroid lobe, in turn, is mobilized ⁽³⁾, the lateral surface of each lobe is cleared by the finger, the middle thyroid vein if present is divided between ligatures ⁽¹⁵⁾. The superior thyroid pedicle is ligated within the upper pole of the gland to avoid damage to the external laryngeal branch of superior laryngeal nerve ⁽³⁾. If possible double ligature should be applied to the upper stump & the lobe drawn forward & medially to search for the inferior thyroid artery & recurrent laryngeal nerve ⁽¹⁵⁾. Inferior thyroid veins are then ligated & divided ⁽³⁾. The inferior thyroid arteries are not routinely ligated to preserve blood supply to the parathyroid, but the arteries may be in continuity of divided between ligatures ⁽³⁾. The RLN should be identified in its course in the whole operative field. It also should first be sought below the level of the inferior thyroid as it passes obliquely upwards and forwards. This course accentuated by mobilization of the thyroid lobe. If the nerve is not immediately seen, it can usually be palpated as a taut strand ⁽²⁾. Identification of the nerve is helped by traction on united ligature on the trunk of the artery ⁽³⁾. The nerve passes into the larynx immediately behind the

inferior cornu of the thyroid cartilage which therefore a very important landmark ⁽²⁾. The RLN contains motor fibers innervating the abductor muscles of the true vocal cord ⁽⁵⁾. The parathyroid should be identified before resection of the thyroid gland; moreover ligatures near the hilum of the parathyroid as well as excessive use of the diathermy should be avoided to limit the risk of devascularisation of the parathyroid or damage to RLN ⁽³⁾. In general, visualization of RLN and ligation of inferior thyroid artery reduced the risk of nodular tissue in the remnant thyroid significantly ⁽¹⁶⁾.

Postoperative complications:

Surgical procedure on the thyroid gland is generally safe and well tolerated. Nevertheless the occasional complications following such surgery may be life-threatening or at least disabling ⁽⁹⁾:

- a. Bleeding with hematoma formation deep to the cervical fascia usually due to slipped ligature on sup.thyr. pedicle or from remnant ⁽²⁾.
- b. Respiratory obstruction usually caused by laryngeal edema due to tension hematoma, trauma to the larynx by anesthetic intubation and surgical manipulation ⁽²⁾, and tracheomalacia⁽¹⁷⁾.
- c. Thyroid insufficiency usually occurs as an insidious process over a period of 2-5 years after surgery at an incidence of 20-45%. It may be due to alteration of the autoimmune process

leading to destruction of thyroid cells⁽³⁾.

d. Thyroid crisis is an acute exacerbation of the hyperthyroidism occurs in thyrotoxic patient inadequately prepared for surgery, it is extremely rare now⁽²⁾.

e. Cosmetic and infective complications are important to the patient as the wound is often exposed. These complications include wound infection, stitch abscess, hypertrophic scar, keloid, rail-road scar and scar adherent to the trachea and move with deglutition⁽⁹⁾.

f. Injury to the external branch of the sup.laryng. nerve results in difficulty in shouting or singing or high notes. Its injury can be reduced by adequate visualization of the upper pole of the thyroid gland & by individual ligation of sup.thyroid vessels low on the thyroid gland.

g. Parathyroid insufficiency: the incidence should be lower than 0.5%⁽²⁾. Parathyroid insufficiency or hyperparathyroidism is an important postoperative complication which may be transient or permanent and result in hypocalcaemia⁽⁵⁾. Hypocalcaemia following thyroid surgery is mainly due to impaired parathyroid function due to trauma, devascularisation, or inadvertent excision of the parathyroid glands. In the minority of cases hypocalcaemia may be due to haemodilution^(9,18,19), Calcitonin release and hungry bone syndrome in thyrotoxic patient^(9,18). The incidence of hypocalcaemia varies with the size and degree of invasions by tumor,

extent of thyroidectomy and experience of the surgeon⁽⁴⁾. For subtotal thyroidectomy up to 5% of patients may suffer mild transient hyperparathyroidism, for total thyroidectomy between 1% and 15% will suffer permanent effects⁽⁵⁾. Hypocalcaemia might be asymptomatic or causing symptoms usually 2-5 days after operation and may require treatment⁽²⁾. Serum calcium level should be measured on the 4th or 5th postoperative day unless the patient is tetanic in which case it is measured at once⁽⁵⁾. Most cases recover spontaneously within few months. Hyperparathyroidism persists after 1 year must be considered permanent^(2,4,9,18). Many studies have been done to clear out the effect of ligation of inf. Thyr. artery on hypocalcaemia. A study done on 279 patients with benign nodular goiter at 1966 showed that bilateral ligation of inferior thyr.artery in bilobed approach as well as entire preparation towards the ligament of berry permits reduction in permanent hypocalcaemia to 0.3%,⁽²⁰⁾. Bilateral ligation of inferior thyroid artery is not an important causal factor for the occurrence of postoperative hypocalcaemia after subtotal thyroidectomy⁽²¹⁾. Truncal ligation of inf. Thyroid artery during subtotal thyroidectomy has no effect on the incidence of hypocalcaemia after thyroidectomy⁽²²⁾.

h. Recurrent laryng.nerve paralysis: its incidence may be correlated to the different diseases of the thyroid glands^(4,9,17), to the operative procedure⁽²³⁾,

Web Site: <https://jmed.utq.edu.iq>

Email: utjmed@utq.edu.iq

ISSN (Print):1992-92 18, ISSN(Online):1992-92 18

DOI: <https://doi.org/10.32792/utq/utjmed/16/2/9>

to the intraoperative exploration of the nerve, and to the surgeon state of training^(2,4,8,17,23). Identification of RLN during surgery may be assisted by palpation (cordlike) or inspection (glistening white cord). Careful dissection is important in the region of the inf. Thy.artery. Attention must be focused on the nerve where it passes deep to or through the layers of the ligament of Berry^(9,24). RLN paralysis may be unilateral bilateral, transient or i.

permanent⁽²⁾. Transient paralysis is caused by traction or stretching of the nerve. Permanent paralysis is caused by ligation or division of the nerve⁽⁴⁾. Unilateral paralysis may be asymptomatic or cause voice changes which may be compensated by other side vocal cord within 6-12 months. Bilateral RLN palsy is rare and may lead to airway obstruction and require emergency tracheostomy^(4,9)

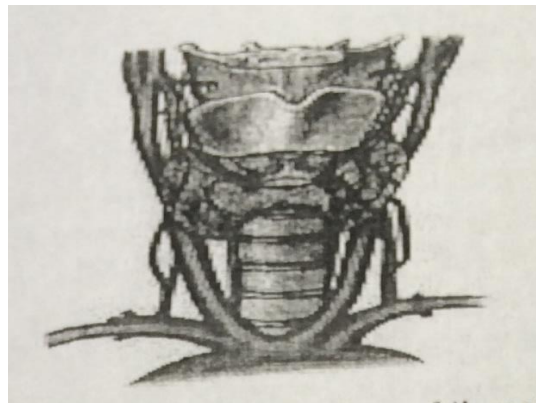


Figure 1: Thyroid anatomy, distribution of thyroid arteries with associated laryngeal nerve, posterior view.

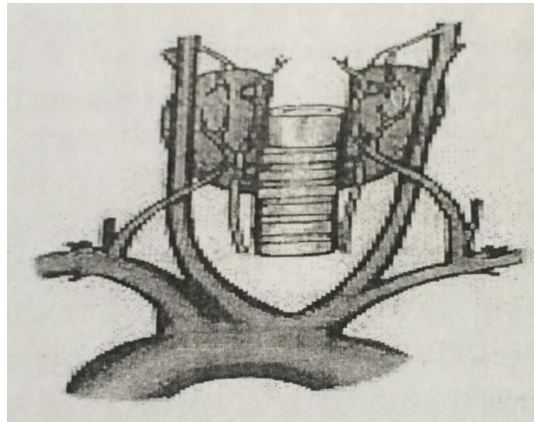


Figure 2: Thyroid anatomy, Distribution of thyroid arteries with associated laryngeal nerve, posterior view.

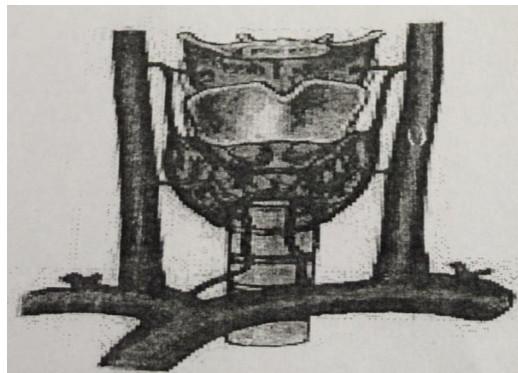


Figure 3: Thyroid anatomy, Distribution of thyroid veins.

Patients & Methods:

A prospective study of 30 patients with goiter underwent different surgical procedure by different surgeons from Jan. 2016- Jan 2017 was conducted. The patients age range 15-55 years with mean age of 33.6 years. In

general, 28 patients were female (93.3%), and 6.7%) were males, with females to male ratio of 14:1. Information from patients were obtained including name, sex, age, address and clinical notes: the inferior thyroid artery was ligated or not, post-

Web Site: <https://jmed.utq.edu.iq>

Email: utjmed@utq.edu.iq

ISSN (Print):1992-92 18, ISSN(Online):1992-92 18

DOI: <https://doi.org/10.32792/utq/utjmed/16/2/9>

operative complications in the immediate post-operative period especially hemorrhage which might be revealed in the drain or concealed as hematoma, signs of hypocalcaemia, RLN affection.

ligation was studied. During the procedure of thyroidectomy the majority of surgeons perform thyroid resection without ligation of the inf.thyr.artery as a routine procedure. Other surgeons used to ligate this artery either temporarily by wrapping the trunk of the artery using a silk suture (banding) on artery forceps till the end of the thyroid resection where the artery is released and hemostasis is secured. Alternatively, the inferior thyroid artery is permanently ligated either in continuity or by ligation-division manoeuver.

The follow up period was mainly during the hospital stay of the patients and then when the patient reexamined at the removal of stiches. Intraoperatively the inf.thyr.artery

Results:-

Table 1: Age and sex distribution of patient samples

Age/ years	Male	Female	Total	Ratio
10-19	-	1	1	33.3
20-29	1	9	10	33.3
30-39	-	8	8	26.66
40-49	1	8	9	30
50-59	-	2	2	6.66
Total	2	28	30	100

Table 2: Types of goiter at presentations

Type of goiter	No. of patients	Ratio
Diffuse goiter	3	10
Simple multinodular	12	40
Toxic multinodular	5	16.67
Solitary nodule	10	33.33
Total	30	100

Table 3: Functional state of thyroid gland

Type of function	No. of patients	Ratio
Euthyroid	22	73.33
Hyperthyroid	8	26.67
Hypothyroid	-	-
Total	30	100

Table 4: Type of operations done

Type of function	No. of patients	Ratio
Isthmusectomy	-	-
Lobectomy	9	30
Subtotal Thyroidectomy	21	70
Total thyroidectomy	-	-
Total	30	100

Table 5: Truncal ligation of the inferior thyroid artery in relation to thyroid operations

Operation	Ligation of IT. ar	%	Without ligation of IT.ar	%	Total	%
Lobectomy	2	6.67	7	23.33	9	30
Subtotal thyroidectomy	10	33.33	11	36.67	21	70
Total	12	40	18	60	30	100

Table 6: Truncal ligation of the inferior thyroid artery in relation to functional state of thyroid gland

Functional state of thyroid	No. of patients	IT.ar ligated	%	IT.ar not ligated	%
Toxic	8	8	26.67	-	-
Nom-toxic	22	4	13.33	18	60
Total	30	12	40	18	60

Table 7: Early postoperative complications in relation to ligation of IT.ar.

Type of complication	With ligation of IT.ar. N=12	%	Without ligation of IT.ar. N=18	%	Total N=30	%
Haemorrhage	1	8.3	3	16.6	4	13.33
Tetany	1	8.3	1	5.55	2	6.66
RLN affection	1	8.3	1	5.55	2	6.66
Thyroid crisis	-	-	-	-	-	-
Total	3	25	5	27.77	8	26.99

Table 8: Early postoperative complication in relation to extent of thyroidectomy

Type of operation	Haemorrhage	%	Tetany	%	RLN affection	%	Total	%
Lobectomy N=9	1	11.11	-	-	-	-	1	11.11
Subtotal thyroidectomy N=21	3	14.28	2	9.52	2	9.52	7	33.33
Total N=30	4	13.33	2	6.66	2	6.66	8	26.66

Table 9: Comparison between our study and other studies about RLN affection following thyroidectomy

The study	Al-Fakhn study 1998	Freidrich study 1998	Baghdad study 1999	Our study 2004
No. of patients at the study	116	725	100	30
RLN affection	5 (4.3%)	55 (7.6%)	6 (6%)	2 (6.6%)

Table10: Comparison between our study and other studies about postoperative hypocalcaemia following thyroidectomy

The study	Al-Rasheed hospital study 1998	Thomouch&sekulla study 1998	Our study 2004
No. of patients in the study	96	220	30
Hypocalcaemia (Tetany)	(6.25%)	(7.3%)	(6.6%)

1. Table (1), shows the age & sex distribution of the 30 patients included in the study. In fact 28 females (93.33%) & 2 males (6.66%) were divided into 5 ages groups range from 15-55 years with mean age of 33.6 years . Age group (20-29 years) represented the largest age group 33.3%, then age group (40-49 years) represented 30% of patients, & age group (30-39 years) represented 26.6% of patients. The smallest age group was (10-19 years) about 3.3%. Male patients distributed in the age groups 20-29 years & 40-49 years.

2. Table (2) shows types of goiter at presentation. Twelve patients (40%) presented with simple multinodular goiter. 10 patient (33.3%) presented with solitary thyroid nodule .5 patients (16.67%) presented with toxic multinodular& 3 patients (10%) presented with clinically diffuse goiter.

3. Table (3) shows the functional state of thyroid gland. Twenty-two patients (73.3%) were euthyroid, while 8 patients (26.6%) were hyper thyroid.

4. Table (4) shows type of operative procedure. Twenty-one patients (70%) were subtotal thyroidectomy. 9 operations (30%) were lobectomy on the affected side either for toxic or cystic nodular swelling. There was no total thyroidectomy.

5. Table (5) shows truncal ligation of inferior thyroid artery in relation to the type of thyroid surgery. Nine patients (30%) underwent lobectomy in which 2 operations (6.67%) involved ligation of ITA whether in continuity or ligation division procedure. 7 operations (23.3%) done without ligaton of ITA. Twenty-one patients (70%) were subtotal thyroidectomy where ITA was ligated in 10 operations (33.3%), the artery was not ligated in 11 operations (33.67%). The total no. of operations in which ligation of ITA was done in 12 operations (40%) while those in which the artery was not ligated are 18 operations (60%).

6. Table (6) shows truncal ligation of ITA in relation to the functional

Web Site: <https://jmed.utq.edu.iq>

Email: utjmed@utq.edu.iq

ISSN (Print):1992-92 18, ISSN(Online):1992-92 18

DOI: <https://doi.org/10.32792/utq/utjmed/16/2/9>

state of thyroid gland .Eight patients (26.67%) with toxic goiter underwent thyroidectomy with ligation of ITA , 4 patients (13.3%) with euthyroid underwent thyroidectomy with ligation of ITA . 18 patients (60%) with euthyroid goiter underwent thyroidectomy without ligation of ITA .

7. Table (7) shows early postoperative complications in relation to the ligation of the inferior thyroid artery :

There were 8 cases (26.6%) showed early postoperative complications following thyroidectomy. Also, 3 cases (25%) were reported after thyroidectomy with ligation of ITA as:

- One case (8.3%) with haematoma .
- One case (8.3%) with tetany.
- One case (8.3%) with RLN affection.
- five cases (27.77%) of thyroidectomy without ligation of the ITA showed postoperative complications as follows :
- Three cases (16.66%) with haematoma.
- One case (5.55%) with telany.
- One case (5.55%) with RLN affection.

9- Table (8) shows early postoperative complications in relation to the extent of thyroidectomy (type of operation).The overall postoperative complications were 8 cases (26.6%) reported as:-

- One case (11.1%) after lobectomy showed haematoma.
- Seven cases (23%) after subtotal thyroidectomy showed postoperative complications as follows:
- Three case (14.28%) with haematoma .
- Two case (9.52%) with tetany .
- Two cases (9.52%) with RLN affection.

Discussion:

30 patients with goiter were studied prospectively .28 patients (93.3%) were females and 2 patients (6.7%) were males with females /males ratio of 14:1 .The most common age group of patients with goiter at presentation 20-40 years ⁽²⁵⁾. In our study most patients with goiter rank in the age group of 20-50 years (92%). The most common type of goiter at presentation is the multinodular goiter followed by the clinically solitary nodules ⁽²⁵⁾ . In our study simple multinodular goiter was the most common type represented 40% of patients followed by clinically solitary nodules 10 cases.

Most patients with goiter present in the euthyroid state ⁽²⁵⁾ . In our study 73.3% of patients were euthyroid while 26.7% of patients were hyperthyroid. The standard surgical procedure for multinodular goiter is the subtotal thyroidectomy ^(2,4,14) . In our study subtotal thyroidectomy was performed in 70% of patients. The mortality rate

from thyroidectomy is variable (0-1.9%)^(4,5).

In our study mortality rate was zero. The ITAs are not routinely ligated during thyroidectomy to preserve blood supply to the parathyroid, in addition, to avoid inadvertent injury to the RLN as this nerve comes into a direct relationship with the terminal branches of the ITA^(2,3). In our study 18 patients (60%) underwent thyroidectomy without ligation of the ITA, while 12 patients (40%) underwent thyroidectomy with the ligation of these arteries. The thyroidectomies without ligation of the ITA were distributed as:

- 7 cases (32.33%) as lobectomy.
- 11 cases (36.67%) as subtotal thyroidectomy.
- Thyroidectomies with ligation of the ITA were distributed as :
- 10 cases (33.3%) as subtotal thyroidectomy.
- 2 cases (6.7%) as lobectomy.

This can be explained as a step to prevent intraoperative bleeding in relation to the extent of resection. The ligation of the ITA was practiced in two ways:

- The artery is either ligated temporarily during the procedure of thyroidectomy (Intraoperatively only) by wrapping the trunk of the artery with a silk suture without knotting (banding) on an artery –forceps and after the goiter has been excised (each

lobe on its merit) the artery is released and haemostasis secured .

- The other way is by permanent ligation were surgeons attempted ligation of the ITA in continuity i.e. without division , this step may put blood supply of parathyroids in jeopardy , or they ligate the artery at its terminal branches close to the thyroid capsule, this may carry small risk of injury to the RLN in the vicinity.
- The ITA may be ligated and divided by other surgeons.

We noticed that most surgeons who ligate the trunk of ITA do so without being worried of parathyroid ischemia after subtotal thyroidectomy in favour of the fact that rich collaterals will develop and supply parathyroid sufficiently. The relationship between ligation of ITA and the functional state of the thyroid glands was studied in this thesis. We found that 8 cases (26.6%) with toxic goiter were treated by subtotal thyroidectomy in which ligation of ITA has occurred. This is to get rid of troublesome bleeding which may occur from this highly vascular toxic goiter , while only 4 cases (13.3%) with euthyroid goiter (out of 22 cases) underwent thyroidectomy with ligation of ITA , though the remainder euthyroid patients underwent the operation without ligation of this artery as long as intraoperative bleeding is acceptable .Ligation of ITA in these 4 cases euthyroid goiter may be practiced in relation to the large size of the goiter which may cause

Web Site: <https://jmed.utq.edu.iq>

Email: utjmed@utq.edu.iq

ISSN (Print):1992-92 18, ISSN(Online):1992-92 18

DOI: <https://doi.org/10.32792/utq/utjmed/16/2/9>

continuous oozing intra and postoperatively . This means that surgeons may practice the ligation of ITA during thyroidectomy for toxic goiter, they may or may not ligate this artery during thyroidectomy for toxic euthyroid goiter, and other surgeons will not ligate the ITA in either.

Regarding immediate postoperative complications following thyroidectomy in relation to the ligation of ITA we found that 3 cases (25%) developed complications following ligation of ITA whether truncal ligation in continuity or by ligation division maneuvers as follows :

- Hemorrhage in 1 case (8.3%) revealed in the redivac drain (>50 cc).
- Tetany in 1 case (8.3%) manifested as carpedal spasm.
- RLN affection in one case (8.3%) manifested as hoarseness of voice (transient due to manipulation).
- Sufficient attention to the course of RLN during ligation of ITA is necessary since this nerve is vulnerable to injury during this process ⁽²⁶⁾.
- 5 cases (27.77%) developed postoperative complications following thyroidectomy without ligation of ITA as follows :
- Haemorrhage in 3 cases (16.66%) revealed in the redivac drain or concealed as subcutaneous hematoma.
- Tetany in 1 case (5.55%) . RLN affection in 1 case (5.55%).

In fact, these complications may be attributed to the size of goiter and extent of resection. The incidence of postoperative hematoma reported in the studies is 4.4% ⁽¹²⁾. In our study hematoma represented 13.3%. The incidence of RLN affection is 3% ⁽²⁾. Its incidence in our study was 6.66% in both procedures whether the artery was ligated or not. Exposure of RLN during surgery while attempting ligation of ITA is associated with high incidence of transient palsy ^(4,14,27) . RLN affection following ligation of ITA (8.3%) is relatively comparable to those following operations without ligation 6% and statistically not significant difference since:-1 case out of 12 cases of ligation developed RLN affection, similarity 1 case out of 18 cases without ligation developed RLN affection. The incidence of transient post-operative hypocalcaemia is variable from 0.6-20% of cases ^(14,18,25). In our study the incidence of hypocalcaemia (tetany) was 6.6% in which 1 case developed tetany after ligation and 1 case developed tetany after without ligation of the artery, again no significant difference exists. This coincides with the fact that truncal ligation of ITA has no effect on and it is not an important factor for the occurrence of postoperative hypocalcaemia after subtotal thyroidectomy ^(21,22) . Extent of resection had a great impact on the rate of postoperative hyperparathyroidism (hypocalcaemia) in bilateral thyroid surgery ⁽²⁸⁾. In our study subtotal thyroidectomy was associated with

Web Site: <https://jmed.utq.edu.iq>

Email: utjmed@utq.edu.iq

ISSN (Print):1992-92 18, ISSN(Online):1992-92 18

DOI: <https://doi.org/10.32792/utq/utjmed/16/2/9>

6.6% postop. Hypocalcaemia whether the artery was ligated or not.

From this study the postoperative complications developed following ligation of ITA were 3 cases (25%) out of 12 cases i.e. one fourth of the total operations with ligation. While 5 cases (27%) out of 18 cases of thyroidectomy without ligation (developed postoperative complications is one fourth of the total operation without ligation). This ascertain that ligation of ITA has no effect on post thyroidectomy complications. Table (9):- shows comparison between our study and results of other studies evaluated RLN affection following subtotal thyroidectomy whether ITA was ligated or not in different localities. AL-Fakhri study, Friedrich study & Baghdad hospital study showed 4.3%, 76%, 6% respectively

References:

1. Richard S. Snell Clinical Anatomy, 7th. ed. 2004.
2. Zygmunt H. Krukowski, (Thyroid gland) in Short practice of surgery 3th ed. (Arnold 2000).
3. Mohammed Kenawy, Alaa Mousa. (Endocrine surg.) In Kasr El Aini Introduction to surg. 3ed. ed. 2004.
4. Gregory P. Sadle, Orio H. Clark (thyroid & parathyroid) in principle of surg. by Seywour Schwartz, 7thed. New York 1999, 1661_1713.
5. Sabiston D.C. Text book of surg. (The Thyroid Gland) 15th ed.1997.
6. Safar SB. Al-Faris H.anatomical variations of RLN in thyroid sur. 1986.
7. Last RJ. Anatomy, 6thed.
8. Bowden REM.The surgical anatomy of RLN. Br. J. surg. 1955, 153-163.
9. John S.Kukora & James D. Hardy,(complications of thyroid & parathyroid surg.) in: complications in thyroid surg. and their management by James Hardy, 4th ed. WB. Sauder's 1981, 295.
10. Endocrine Disorders and Endocrine surg. update Jan. 2005.

(29,30,31) . Our study showed 6.6% incidence. Also, table (10) :- shows comparison between our study and other studies concerning postoperative hypocalcaemia manifested as tetany following thyroidectomy whether the artery was ligated or not .Al-Rasheed hospital study, Thomauch&Sekulla study showed 6.25%, 7.3% respectively (28,32) . In our study the incidence was 6.66%.

Conclusions:

There is no statistically significant difference in the development of postoperative complications that may accompany thyroidectomy whether the ITA was ligated during the procedure or not, revealing that the ITA ligation has no effect on the development of these complications.

Web Site: <https://jmed.utq.edu.iq>

Email: utjmed@utq.edu.iq

ISSN (Print):1992-92 18, ISSN(Online):1992-92 18

DOI: <https://doi.org/10.32792/utq/utjmed/16/2/9>

11. Abdul Rahman Al Janabi: Carcinoma of thyroid gland. Iraqi Medical Journal 1979.
12. M. H. Layth (one year experience in thyroid surg.) in: Iraqi Army Med. Journal vol. 4, 1991.
13. M.A.R Al- Falluji (Historical background) in: William Heinemann medical books, Postgraduate of surg. 1986.
14. Johan Webb. "Endocrine surg. , Thyroid gland" in: Scott. An Aid to clinical surg. 6th. ed. by Rubin C. N. Williamson 1998.
15. R. F. Rintoul "Thyroid and parathyroid" in: Farquharson's Textbook of operative surg. 8th ed. 1995.
16. Mann B. SchaleP"Thyroid morphology and function after surg. Treatment if thyroid disease " . Germany 1996 .
17. A.A. Abdel Rahim 'M.E. Ahmed & M.A Hassan." Respiraty complications after thyroidectomy and the need for tracheostomy patients with large goiter."British journal of surg. 1999;86 .
18. Francois Patto& Frederic Combemale ."Hypocalcaemia following thyroid surgery , Incidence &Prediction of outcome world Journal of surgery 1998,22 .
19. Catz B.&PerzikS."Total thyroidectomy in management of thyrotoxic&euthyroid Grave's Disease "AMJ.surgery 1989,118:434 .
20. Klamar F.,Bancer ."Standerized morphology adjusted resection in treatment of benign nodular struma".
21. AraujoFilhoVJ , Silva F.G.B. "Importance of ligation of inferior thyroid artery in parathyroid function after subtotal thyroidectomy ".July-Aug. 2000-55(4) .
22. Dolapci M. , Kama NA. "Truncal ligation of inferior thyroid artery does not affect the incidence of hypocalcaemia after thyroidectomy ". Study on 216 patians-turkey (90-1991)surgery 2000 Apr. ,116 .
23. Therman M. &Feltramp M."RLN paralysis after thyroid operations, Etiology & consequences ". Chirup Sep. 1998;69(9) .
24. WbeelerMacolm ."Thyroid surgery & RLN ".British Journal of surgery .1999;86 .
25. BarnoutiN.H."Iraqi Pattern of goiter ".Iraqi Army Medical Journal vol. 7. 1995 .
26. Lu J. ,Ebrahim NA, N adim Y ."Anerior Approach to cervical spine "2000 Aug .
27. W. Lamade ,KRenz, "Effect of training on RLN injury ". British Journal of surgery 1999;86 .
28. ThomuschO., Sekulla C. " Impact of surgical technique on post operative hypothyroidism in bilateral thyroid surgery." National Library of Medicine . Surg.2003 Feb.,133 .

29. Al-Fakhry N. ,Runkel N. , Buhr H. "Rate of complications with systemic exposure of the RLN and parathyroid in the operation for benign thyroid disease . ZentralblChir1998 ; 123 (1) .
30. Friedric T, SteinertM,Keitel R. "Incidence of damage to RLN in surgical therapy of various thyroid gland disease .Respective study .Zentralblchir 1998;123(1) .
31. Ahmed Jarrallah , "RLN injury after thyroid gland surgery ' in Baghdad teaching hospital .1998 .
32. Abdul Ameer Al-Darraj . "Morbidity of thyroid surgery " In Al-Rasheed Hospital. 1998.

ربط الشريان الدرقي الاسفل في عملية أستئصال الغدة الدرقية

د . حيدر هادي منشد - اختصاصي الجراحة العامة

الخلاصة

تمهيد: عملية استئصال الغدة الدرقية من العمليات الجراحية الشائعة ورغم ان مضاعفاتها نادرة الحدوث عند الجراحين المتمرسين إلا أنها تعتبر ذات وقع شديد على المرضى.

الدراسة: للفترة من كانون الثاني ٢٠٠٤ لغاية كانون الثاني ٢٠٠٥ وفي دراسة مستقبلية تمت دراسة ٣٠ مريضا خضعوا لعمليات جراحية مختلفة في الغدة الدرقية من قبل جراحين اختصاص لدواعي مرضية متعددة في هذه الغدة. شملت الدراسة ٢٨ مريضا من الإناث (٣,٣ - ٩%) ومرضى من الذكور (٦,٧%) تراوحت اعمارهم بين ١٥-٥٥ سنة بمتوسط عمر (٣٣,٦) سنة . كان معظم المرضى يعانون من دراق عقدي متعدد وبنسبة أقل من عقدة درقية منفردة أو دراق واسع (سريريا) وقد أجريت لهم عمليات جراحية متعددة. كان الاستئصال الدرقي تحت كامل هو الأكثر شيوعاً بين تلك العمليات.

الهدف: كان الهدف من الدراسة المقارنة بين المضاعفات الناتجة بعد العمليات الجراحية حيث يتم ربط الشريان الدرقي الأسفل مع تلك الناتجة عن العمليات التي تجرى بدون ربط هذا الشريان. لقد ركزت الدراسة على طرق ربط الشريان الدرقي الأسفل أثناء العمليات الجراحية ومدى تأثير ذلك على المضاعفات الناتجة وخصوصا النزف الدموي، إصابات العصب الحنجري الراجع ونقص الكالسيوم في الدم.

النتائج: أظهرت الدراسة ما يلي:

من أصل ٣٠ عملية جراحية تم ربط الشريان الدرقي الأسفل في ١٢ عملية (٤٠%)، فيما لم يربط الشريان في ١٨ عملية (٦٠%).

كان استئصال الدرقية تحت الكامل أكثر العمليات التي تم فيها ربط الشريان (١٠ عملية) بينما تم ربط الشريان في عمليتين تضمنت رفع أحد فصي الغدة.

تركزت عمليات ربط الشريان على حالات الدراق السام لتفادي النزف الدموي فيها، فيما تم ربطه في عمليات الدراق غير السام في حالة كون الدراق هائل الحجم.

كانت نسبة المضاعفات بعد ربط الشريان الدرقي (٢٥%) فيما كانت نسبة المضاعفات

عند عدم ربطه (٢٧%) وهذه النسب تمثل الربع لكل من العمليات ذات الربط للشريان و

العمليات التي جرت بدون ربط الشريان.

الاستنتاج: أظهرت الدراسة عدم وجود فرق إحصائي مهم في حدوث المضاعفات بعد

العمليات سواء تم ربط الشريان الدرقي الأسفل أم لم يتم.