

Native Arteriovenous Fistula Creation in Al – Hussein Teaching Hospital

Dr. Ahmed Abdul – Ameer Daffar (M. B. CH. B., F. I. B. M. S.) *

Dr. Adnan Taan Thamer (M. B. CH. B., C. A. B. M. S., F. R. C. P.)

Dr. Akeel Salman Yosur (M. B. CH. B., F. I. B. M. S.) **

ABSTRACT:

Objective : To present the advantages of native arteriovenous fistula creation in comparison with graft AVF creation in patients with chronic renal failure and on regular hemo – dialysis or those with impending end stage renal disease and that searching for a suitable superficial vein for this purpose is mandatory.

Patients : This is a prospective study of 50 patients for whom an arteriovenous fistula was created in the upper limb under local anaesthesia over a period of about one year (from 1st of January 2013 till 1st of December 2013).

Methods : The case sheets of relevant patients for whom an AVF was created were reviewed to collect information like patient's sex, age, site of AVF, type of anastomosis, etc...

Results: AVF creation was offered for different age groups and for both sexes. Side to side anastomosis was carried out for most patients and the preferred site was the cubital fossa between the brachial artery and a nearby superficial vein. The time of first cannulation after AVF creation was variable depending on several factors. Different complications but no mortality had been recorded perioperatively.

Conclusions: Native AVF creation is always preferred over graft AVF and every effort was made to search for a suitable superficial vein for the purpose of AVF creation. The elbow region was a suitable option for elderly patients and those with comorbidities despite the fact that the more distal location of AVF is associated with less complications. Side to side anastomosis for AVF creation was the procedure of choice and the non dominant upper limb is preferred if possible.

* Medical College / Thi – Qar University (Thi – Qar, Iraq)

** Ibn Al – Nafees Teaching Hospital (Baghdad, Iraq)

Introduction

Strategies of AV dialysis access

With the ever-increasing longevity of the population and physicians' improving ability to treat end-stage renal disease, insertion of vascular access is becoming one of the most common procedures performed by a typical vascular surgeon.

The multidisciplinary approach to a patient who may require AV access affords the clinical team the ability to anticipate access need and allow for time for maturation of an autogenous access. The DOQI guidelines–recommended surgical referral pattern should begin when a patient exhibits a creatinine clearance of less than 25 mL/min or a serum creatinine of greater than 4 mg/dL or when AV access is anticipated within 1 year.^[1] This interval allows for evaluation, placement, maturation, and possible revision without the need for catheter insertion in the most ideal circumstance. Although this interval may be ideal, however, it is often not the case, and late presentation to a dialysis unit is associated with increased mortality and increased need for temporary vascular access.^[2] Additionally the primary AA requires 3 months to “mature” before cannulation and is the primary access of choice.

Strategies of access location

The timing of hemodialysis dictates the type of initial access. This decision can be divided into acute, semiacute, and long-term access techniques. Often, as in a patient in whom initial access has failed and who is presently hemodialysis dependent, access is obtained by insertion of a catheter

synchronous with a form of long-term access so that the patient may undergo hemodialysis while the access matures.

Acute Access Location and Strategy

For patients who require immediate dialysis access of less than 3 weeks' duration, a double-lumen cuffed or noncuffed catheter should be inserted into the internal jugular, subclavian or femoral vein.^[3]

Most importantly, the subclavian position should be avoided if the patient is to be considered for an ipsilateral arm access procedure because the incidence of subclavian stenosis or thrombosis or both increases steadily with the presence of a catheter in this position, rendering the extremity useless for insertion of a permanent access.^{[4] [5] [6]}

Semiacute Access Location and Strategy

In a situation in which the patient would require hemodialysis for more than 3 weeks' duration, insertion of a cuffed, tunneled, double-lumen catheter should be considered. These catheters also may be employed in situations in which the patient has exhausted all other options for long-term access or in whom hemodialysis is required while an AA matures. The internal jugular vein is preferred because of its proximity to the atrial-caval junction (allowing for better flow), but with the added emphasis of placing the catheter in the right internal jugular vein because this is associated with fewer complications compared with other insertion sites.^{[7][8]} Insertion into the left

internal jugular vein is associated with an increased rate of stenosis and thrombosis and inadequate flow rates.^{[9] [10]} In contrast to a noncuffed temporary bedside catheter, a cuffed catheter must be inserted in a fluoroscopically capable operating room or interventional suite. Although noncuffed catheters can be inserted using Seldinger technique, cuffed catheters are constructed of a softer Silastic material and must be placed by means of a larger “breakaway” introducer catheter. Aside from complications associated with insertion (hemothorax and pneumothorax), the tunneled cuffed catheter can be relied on to function for an average of 6 months, after which infection, fibrin sheath formation, or thrombosis may curtail usage.^[11] Using endoluminal therapy or percutaneous mechanical techniques, Suchoki and colleagues^[12] were able to prolong average catheter patency to 12.7 months.

Strategies of location and type of access

Preoperative Evaluation

Before consideration of any long-term access procedure, a thorough history and physical examination should be performed. Aspects of prior history, other than typical items of interest to the surgeon, should include type and location of *any indwelling catheters*, even subsequent to removal, given the association with deep vein stenosis^[13]. The surgeon should also evaluate the patient for congestive heart failure, D.M and should make note of the patient’s dominant extremity and

whether the extremity has endured penetrating trauma or recent catheter insertion.^{[14] [15]} The assessment of the vasculature in the chosen limb should include palpation of pulses at all levels and an Allen test, which, if abnormal, may contraindicate a distal AA. The blood pressure of both upper extremities should be measured and compared for difference, indicating more proximal arterial disease. Special attention is given to the status and adequacy of the veins of the hand, wrist, forearm, elbow, and upper arm. A vein is considered adequate if it is visible through the skin with or without a tourniquet applied. In instances in which a prior access has failed, imaging of the arterial or venous system may be necessary to plan a procedure adequately. The use of venous duplex examination may suffice as long as the surgeon recognizes the limitations of the study to detect proximal deep vein stenoses^[16] and the technician dependency.^{[17] [18]} An added advantage of injection venography is the ability to correct underlying lesions that are amenable to such therapy before the access placement.^[19] Lesions that cannot be corrected should disqualify the limb as a potential access site. Preference is given to the nondominant arm over the dominant arm, followed by distal location before proximal location.

TABLE 117-1 -- Indications of Venous Imaging Before Access Insertion

Edema in the extremity in which an access is planned
Collateral vein development in any planned access site
Differential extremity size of the considered limb
Current or previous transvenous catheter, of any type, in the ipsilateral limb
Previous arm, neck, or chest trauma or surgery in venous drainage of planned access site
Multiple previous accesses in the ipsilateral extremity
<i>Adapted from NKF-K/DOQI Clinical practice guidelines for vascular access: Update 2000. Am J Kidney Dis 37:S137-S181, 2001.</i>

Strategies of autogenous access creation

The first autogenous access creation for the purposes of hemodialysis access was the Brescia-Cimino radiocephalic direct wrist access in 1966.^[20] Overall, the AA affords a superior patency of 75% at 4 years, yet has a higher rate of early failure.^[21] Although the AA carries a better patency rate when established, it must be allowed to mature for approximately 6 to 8 weeks, occasionally longer, and may require the patient to undergo insertion of a percutaneous catheter for hemodialysis if referral for creation of the fistula was not timely. In addition,

results of AA creation have been associated with poor results in certain

subsets of patients, such as diabetics or women who underwent forearm AA or in older patients.^[22] The AA carries a much lower rate of complications compared with the PA,^[23] ^[24] ^[25] however, and adequate flows are more easily attainable.

Autogenous Posterior Radial Branch–Cephalic Direct Access

The autogenous posterior radial branch–cephalic direct access (*snuffbox fistula*) is to date the most distal AA described. It consists of an end-to-side anastomosis between the distal cephalic vein and the thenar branch of the radial artery, the pulse of which is usually palpable through the floor of the anatomic snuffbox, created through one incision.

Autogenous Radial-Cephalic Direct Wrist Access

The autogenous radial-cephalic direct wrist access (*Brescia-Cimino fistula*) is perhaps the “gold standard” of AA creation. First described in 1966, this access also has been called the *Cimino fistula* or the *wrist fistula*. It's construction consists of anastomosis between the cephalic vein at the wrist to the radial artery.

Results of the Cimino fistula have been generally good. Similar to most experiences with AA, most failures occur within the first 12 months, beyond which the patency rates are excellent.

Radial-Basilic Forearm Transposition

As an alternative before the use of a more proximal vein in a patient who has failed or is not a candidate for Cimino fistula, transposition of the basilic vein of the forearm to a ventral position with end-to-side radial-basilic anastomosis is a viable option described first by Silva and colleagues,^[26] the results of radial/ulnar–basilic forearm transposition have been similar to that of other forearm AA.

Brachial-Cephalic Direct Elbow Access

Anastomosis of the antecubital veins with the brachial artery can be accomplished with good result. Termed *brachial-cephalic direct elbow access (cephalic turndown or brachial-cephalic fistula)*, this type of AA, which involves anastomosis between the cephalic or basilic vein and the brachial artery, has been suggested in patients with diabetes for its superior flow and maturation rate. Despite favorable results, the fistula has a higher incidence of steal, especially with long donor arteriotomies. The brachial-cephalic fistula also eliminates the remainder of the forearm as a possible site of future access.

Autogenous Brachial-Basilic Upper Arm Transposition

Usually considered the last routine AA alternative of the upper limb, the autogenous brachial-basilic upper arm transposition (basilic transposition) was first described by Dagher and colleagues in 1976.^[27] The procedure

involves mobilization, distal division, and superficial tunneling and transposition of the basilic vein with distal end-to-side anastomosis with the brachial artery.

Lower Extremity Autogenous Access

If all upper extremity dialysis access options have been exhausted, the surgeon may consider the use of the lower extremity for insertion of an AA. Use of a loop of saphenous vein and transposition of the superficial femoral vein has been described; results have been mixed. Lower extremity AA is more likely to fail to mature, to subject the patient to steal syndrome, and to experience thrombosis earlier than upper extremity AA and probably PA as well, in addition to the added morbidity of saphenous harvest and groin wound infection.^[28]

Strategies of prosthetic access insertion

With the advent of safe, reliable, and widely available vascular synthetic, the access options for patients needing hemodialysis grew enormously. A graft material that is resistant to thrombosis or infection and that promotes neoendothelialization has yet to be discovered, however. PTFE is currently preferred over other synthetics, such as Dacron, because of its lower rate of disintegration and better surgical handling. Although the PA may be expected to remain patent on average for approximately 3 to 5 years,^[29]

patency rates may be lower. Advantages of the graft include the large surface area available for cannulation ^[30] ; the ease in cannulation; and the dramatically shorter and more reliable time to maturity for use, an interval on the order of 10 to 14 days. ^[31]

Prosthetic Materials

Sites for insertion are typically the forearm and the upper arm, in either a loop or a straight configuration. When the upper extremity has been exhausted of possible access sites, more unusual sites for insertion may be considered. Among these sites are the axillary artery, with either contralateral axillary vein runoff or runoff into the ipsilateral or contralateral jugular vein. Because of the high incidence of complications, the groin and lower leg can be considered for prosthetic access insertion after exhaustion of all other available sites. The early experience with this location was particularly discouraging and was associated with a high incidence of infection, steal syndrome, and limb loss. ^{[32] [33]}

Aim of study

To present the advantages of native arteriovenous fistula creation in comparison with graft AVF creation in patients with chronic renal failure and on regular hemo – dialysis or those

with impending end stage renal disease and that searching for a

suitable superficial vein for this purpose is mandatory.

Patients and Methods

This is a prospective study of 50 patients suffering from chronic renal failure for different causes (26 females & 24 males) for whom arteriovenous fistulae were created under local anaesthesia from the first of January 2013 till the first of December 2013 in AI – Hussein Teaching Hospital in Thi – Qar governorate.

On admission, a quick but informative history was taken from every patient including age, sex, onset of chronic renal failure, the site of previous double lumen catheters and number of dialysis sessions. Baseline data included patient demographics, presence of comorbid diseases including CHF, hypertension, diabetes mellitus.

Clinical judgment and physical examination were used for selection of patients for native fistula placement. The investigations which were needed before surgery included virology screening for hepatitis B, hepatitis C and HIV and other simple investigations including PCV, random blood sugar, ECG, chest x-ray. Preoperative arterial and venous mapping of the upper extremities by Doppler ultrasound was not obtained prior to access creation and venography for preoperative evaluation of upper extremity veins was not used.

For native fistula placement the brachial or radial artery and nearby superficial vein were exposed using the same incision. Veins too distant from arterial inflow

for standard arteriovenous fistula creation were mobilized and transposed to a more volar position to allow fistula creation. The vein was

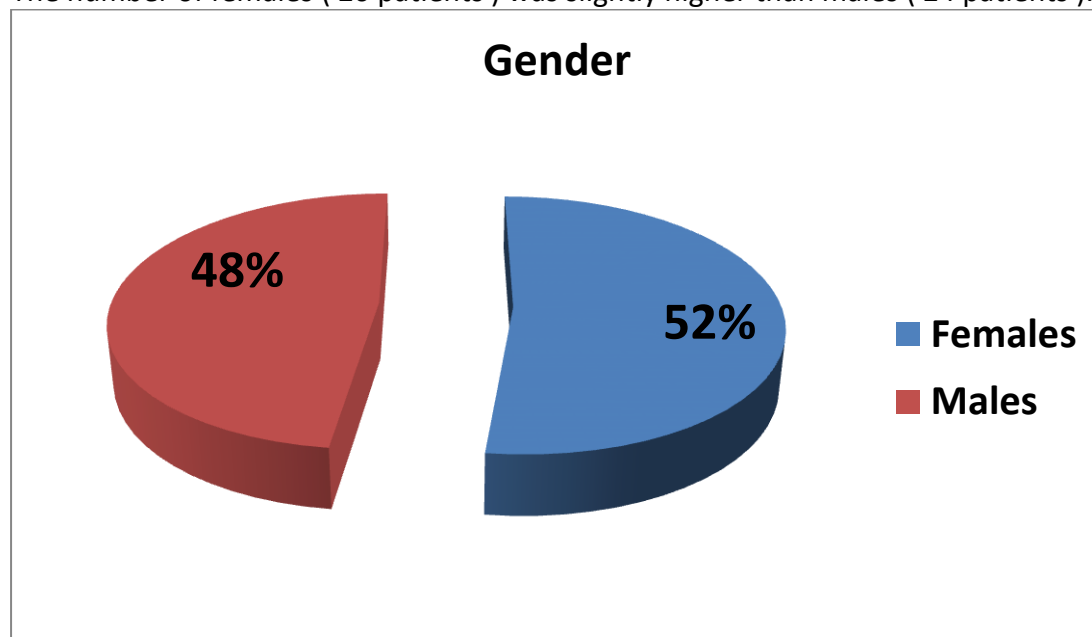
anastomosed to the artery in side to side fashion. In all our patients, no synthetic material was used.

Surgery was done under local anaesthesia using Xylocaine without adrenaline and according to body weight (3 mg per kg) and a corrugate drain was inserted at the end of operation to prevent the development of seroma and/or hematoma and the patient is admitted into the surgical ward of Al – Hussein Teaching Hospital for at least 24 hours postoperatively on anticoagulant and

antibiotics. The purpose of admission was to detect & treat any serious bleeding from the site of anastomosis of the arteriovenous fistula and to ensure that the patient takes injectable anticoagulant and antibiotics. Then follow up continues on outpatient basis for several weeks to several months to detect & treat complications of AVF creation as early as possible and determine the appropriate time at which the AVF becomes ready for use.

Results

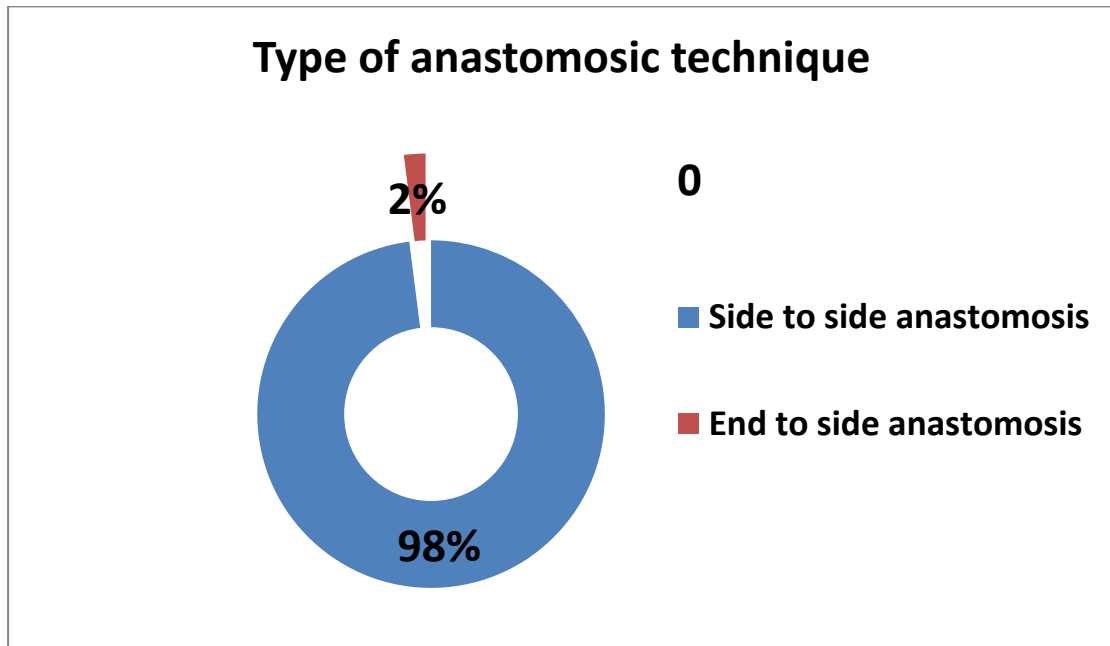
The number of females (26 patients) was slightly higher than males (24 patients).



The youngest patient in this study was 16 years old and the oldest one was 75 years old with a mean age of (42.4) years.

<u>Range of age</u>	<u>No. of patients</u>	<u>Percentage</u>
(10 - 20) years	3	6%
(20 - 30) years	6	12%
(30 - 40) years	11	22%
(40 - 50) years	15	30%
(50 - 60) years	13	26%
(70 - 80) years	2	4%
Total	50	100 %

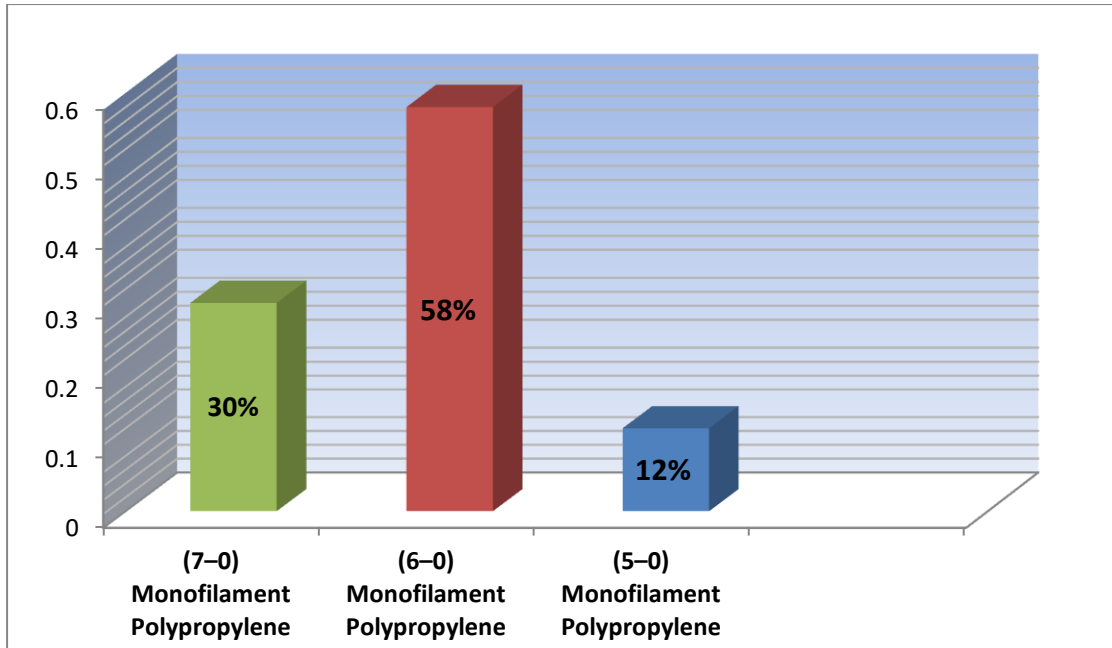
Side to side anastomosis was carried out for most patients 98% (49 patients) with only one patient being operated by side to end anastomosis.



The preferred site of AVF creation was the cubital fossa (proximal forearm) in 47 (94%) patients between the brachial artery and nearby superficial vein. In 3 patients, the AVF was created in the distal forearm between the radial artery and cephalic vein.

<u>Site of AVF creation</u>	<u>The involved vessels of AVF</u>	<u>No. of patients</u>	<u>Percentage</u>
Proximal forearm (cubital fossa)	Brachial artery and cephalic vein	10	20%
Proximal forearm (cubital fossa)	Brachial artery and median cubital vein	25	50%
Proximal forearm (cubital fossa)	Brachial artery and basilic vein	12	24%
Distal forearm	Radial artery and cephalic vein	3	6%

The type of suture material used is always Monofilament Polypropylene (either 6-0 or 7-0). 5-0 Monofilament Polypropylene is used only if 6-0 and 7-0 are not available. The finer the suture material the smaller the needle and the less trauma of the involved vessels chosen for AVF creation.



The non – dominant upper limb is preferred over the dominant upper limb if possible, but this is not always possible.

<u>The upper limb side</u>	<u>No. of patients</u>	<u>Percentage</u>
The dominant upper limb	20	40%
The non dominant upper limb	30	60%
Total	50	100%

All patients for whom an AVF was created had a double lumen catheter in one of the central veins of their body and the operation is always done on elective basis.

<u>Timing of operation</u>	<u>No. of patients</u>	<u>Percentage</u>
Elective basis	50	100%
Urgent basis	Zero	Zero%
Total	50	100%

An AVF takes several weeks for maturation after which it becomes ready for use depending on several factors including the site of AVF creation, the size of chosen vein for AVF creation, the presence or absence of stenosis or obstruction of the proximal draining veins, technical causes,

<u>Duration of maturation</u>	<u>No. of patients</u>	<u>Percentage</u>
6 weeks	10	20%
8 weeks	10	20%
10 weeks	25	50%
16 weeks	2	4%
20 weeks	3	6%
Total	50	100%

The time interval between the first session of dialysis via a double lumen catheter and the AVF creation procedure is very variable depending on several factors.

<u>Time interval between the first session of dialysis and the AVF creation</u>	<u>No. of patients</u>	<u>Percentage</u>
Before any session of dialysis	2	4%
One week	3	6%
Two weeks	5	10%
One month	15	30%
Two months	10	20%
Three months	10	20%
Six months	4	8%
One year	1	2%
Total	50	100%

Certain complications had been encountered perioperatively but no mortality due to AVF creation was recorded. The most serious complication was the development of pseudo-aneurysm at the site of AVF. Other complications include seroma, simple hematoma, infection, steal syndrome, thrombosis at the site of AVF, limb swelling, etc...

<u>Complication</u>	<u>No. of patients</u>	<u>Percentage</u>	<u>Type of treatment</u>
Pseudo-aneurysm	2	4%	Re – exploration (surgery)
Seroma	6	12%	Conservative measures
Simple hematoma	3	6%	Conservative measures
Infection	5	10%	Conservative measures
Steal syndrome	2	4%	Conservative measures
Thrombosis at the site of AVF	2	4%	Creation of another AVF
Transient limb swelling	8	16%	Conservative measures
Permanent limb swelling	2	4%	Conservative measures
Failure rate	5	10%	Accordingly

Discussion

A native vein was utilized for AVF creation in all my patients. This differs with the study made by A. Rabbani and colleagues in which less than 50% of their AVFs were created using a native vein.

In my study the age of patients ranged from (16 to 75) years and this is similar to the study made by A. Rabbani and colleagues in which the age of their patients were ranging from (13 to 75) years.

The failure rate after surgery in my study was 10% either due thrombosis, infection and pseudo – aneurysm development while the failure rate was much higher in the study made by A. Rabbani and colleagues which was about 27% because of the high rate use of synthetic grafts in their surgery. Several complications could be seen in our study but no mortality had been recorded postoperatively. The thesis made by A. Rabbani and colleagues mentioned that a mortality rate of 35% had been recognized added to the different complications after AVF creation and this again is due to the high rate use of synthetic grafts. This suggests improved access survival and function for native AVF when compared with graft AVF. Financial reasons as well as less infection and occlusion rate and lower morbidity rate of native AVFs promoted us to search carefully for suitable superficial veins in the upper limb for the purpose of native AVF creation.

However, the prevalence of AVF is not high in Iraq due to several reasons including the frequent need for emergent dialysis, poor pre – end stage renal disease programs and planning and the patient's resistance

to the reality of impending end stage renal disease. This differs from the developed countries in which the prevalence of AVF was higher reaching 84% in Japan.

The timing of first cannulation after the surgical procedure is variable and depends on several factors (size of chosen artery and whether it's affected by atherosclerosis or not, size of chosen vein and the nature of it's continuity and it's tributaries, technical causes, the size of arteriotomy & venotomy of the chosen vessels, etc...).

In our study, 20% of AVFs became ready for use after 6 weeks and 20% after 8 weeks and 50% after 10 weeks. This parallels studies made in different countries (Japan, Germany, Spain, France and Iran).

The optimal site of AVF creation is the elbow region especially for elderly patients and those with comorbidities (hypertension, diabetes mellitus, heart failure, etc...) and the preferred vein is either the median cubital vein or cephalic vein rather than the basilica vein and this fact was true for both my patients and those of A. Rabbani and colleagues. The non dominant upper limb is preferred over the dominant one in my study.

In my study, all AVF were created by a vascular surgeon exclusively which was me. while A. Rabbani and colleagues mentioned that general surgeons and vascular surgeon share the work of AVF creation.

Conclusion:

- 1-Native AVF creation is always preferred over AVF graft and every effort was made to search for a suitable superficial vein for the purpose of AVF creation.
- 2-The more distal the location of AVF the less the complications, but the elbow region was a suitable option for elderly patients and those with comorbidities.
- 3-Acceptable results has been obtained by side to side anastomosis between the artery and nearby superficial vein to create an AVF.
- 4- The non dominant upper limb was chosen if possible.
- 5-Complications could be managed well because of close follow up after surgery of AVF creation.

Recommendations

- 1-Every effort should be made to use a native vein for AVF creation.
- 2-The more distal the location of AVF creation the less the complications.
- 3-The elbow region for AVF creation is the most suitable site for elderly patients and those with comorbidities.
- 4-According to my study side to side anastomosis technique is preferred because it's easier practically than end to side anastomosis for AVF creation.
- 5-The non dominant upper limb is preferred for the purpose of AVF creation.
- 6-Close follow up is recommended for patients after surgery of AVF creation to detect and treat complications as early as possible
- 7-The decision of AVF creation should be made not only for those with end stage renal disease but also for those with impending end stage renal disease.

References

1. NKF-K/DOQI Clinical practice guidelines for vascular access: Update 2000. Am J KidneyDis,37:S137-S181,2001.
2. Chesser AM, Baker LR: Temporary vascular access for first dialysis is common, undesirable and usually avoidable. Clin Nephrol 51:228–232, 1999.
3. Bander SJ, Schwab SJ: Central venous angioaccess for hemodialysis and its complications. Semin Dial 5:121–128, 1992.
4. Schwab SJ, Quarles LD, Middleton JP, et al: Hemodialysis-associated subclavian vein stenosis. Kidney Int 33:1156–1159, 1988.
5. Barrett N, Spencer S, McIvor J, Brown EA: Subclavian stenosis: A major complication of subclavian dialysis catheters. Nephrol Dial Transplant 3:423–425, 1988.
6. Spinowitz BS, Galler M, Golden RA, et al: Subclavian vein stenosis as a complication of subclavian catheterization for hemodialysis. Arch Intern Med 147:305–307,1987.
7. Schillinger F, Schillinger D, Montagnac R, Milcent T: Post catheterisation vein stenosis in haemodialysis: Comparative angiographic study of 50 subclavian and 50 internal jugular accesses. Nephrol Dial Transplant 6:722–724, 1991.
- 8 . Cimochofski GE, Worley E, Rutherford WE, et al: Superiority of the internal jugular over the subclavian access for temporary hemodialysis. Nephron 54:1541990.

9. Moss AH, Mclaughlin MM, Lempert KD, Holley JL: Use of a silicone catheter with a Dacron cuff for dialysis short-term vascular access. *Am J Kidney Dis* 12:492–498,1988.
10. DeMeester J, Vanholder R, Ringole S: Factors affecting catheter and technique survival in permanent silicone single lumen dialysis catheters [abstract]. *J Am Soc Nephrol*,3:361A,1992.
11. Schwab SJ, Buller GL, McCann RL, et al: Prospective evaluation of a Dacron cuffed hemodialysis catheter for prolonged use. *Am J Kidney Dis* 11:166–169, 1988.
12. Suchoki P, Conlon P, Knelson M, et al: Silastic cuffed catheters for hemodialysis vascular access: Thrombolytic and mechanical correction of HD catheters malfunction. *Am J Kidney Dis* 28:379–386, 1996.
13. Trerotola SO: Interventional radiology in central venous stenosis and occlusion. *SeminIntervRadiol*,11:291–304,1994.
14. Palder SB, Kirkman RL, Whittmore AD, et al: Vascular access for hemodialysis: Patency rates and results of revision. *Ann Surg* 202:235–239, 1985.
15. Raju S: PTFE grafts for hemodialysis access: Techniques for insertion and management of complications. *Ann Surg* 206:666–673, 1987.
16. Middleton WD, Picus DD, Marx MV, Melson GL: Color Doppler sonography of hemodialysis vascular access: Comparison with angiography. *AJR Am J Roentgenol* 152:633–639,1989.
17. Tordoir JHM, Hoeneveld H, Eikelboom BC, Kitslaar PJEHM: The correlation between clinical and duplex ultrasound parameters and the development of complications in arterio-venous fistulae for hemodialysis. *Eur J Vasc Surg* 4:179–184, 1990.
18. Tordoir JHM, De Bruin HG, Hoeneveld H, et al: Duplex ultrasound scanning in the assessment of arteriovenous fistulas created for hemodialysis access: Comparison with digital subtraction angiography. *J Vasc Surg* 10:122–128, 1989.
19. Glanz S, Bashist B, Gordon DH, et al: Axillary and subclavian vein stenosis: Percutaneous angioplasty. *Radiology* 168:371–373, 1988.
20. Brescia M, Cimino J, Appel K, et al: Chronic hemodialysis using venipuncture and a surgically created arteriovenous fistula. *N Engl J Med* 275:1089–1092, 1966.
21. Rutherford R (ed): *Vascular Surgery*, 5th ed. Philadelphia, WB Saunders, 2000.
22. Miller PE, Tolwani A, Luscly CP, et al: Predictors of adequacy of arteriovenous fistulas in hemodialysis patients. *Kidney Int* 56:275–280, 1999.
23. Palder SB, Kirkman RL, Whittmore AD, et al: Vascular access for hemodialysis: Patency rates and results of revision. *Ann Surg* 202:235–239, 1985.
24. Kinnaert P, Vereerstraeten P, Toussaint C, Van Geertruyden J: Nine years' experience with internal arteriovenous fistulas for hemodialysis: Study of some factors influencing results. *Br J Surg* 64:242–246, 1977.
25. Kherlakian GM, Roedersheimer LR, Arbaugh JJ, et al: Comparison of autogenous fistula versus expanded polytetrafluoroethylene graft fistula for angioaccess in hemodialysis. *Am J Surg* 152:238–243, 1986.
26. Silva MB, Hobson RW, Pappas PJ, et al: Vein transposition in the forearm for autogenous hemodialysis access. *J Vasc Surg* 26:981–988, 1997.
27. Dagher F, Gelber R, Ramos E, et al: The use of basilic vein and brachial artery as an A-V fistula for long term hemodialysis. *J Surg Res* 20:373–376, 1976.
28. Illig KA, Orloff M, Lyden SP, et al: Transposed saphenous vein arteriovenous

- fistula revisited: New technology for an old idea. *Cardiovasc Surg* 10:212–215, 2002.
29. Albers F: Causes of hemodialysis access failure. *Adv Ren Replace Ther* 1:107–118,1994.
30. Windus DW: Permanent vascular access: A nephrologist's view. *Am J Kidney Dis* 21:457–471,1993.
31. Owens ML, Stabile BE, Gahr JA, Wilson SE: Vascular grafts for hemodialysis: Evaluation of sites and materials. *Dial Transplant* 8:521–530, 1979
32. Mandel ST, McDougal EG: Popliteal artery to saphenous vein vascular access for hemodialysis. *Surg Gynecol Obstet* 160:358–359, 1985.
33. Connolly JE, Brownell DA, Levine EF, et al: Complications of renal dialysis access procedures. *Arch Surg* 119:1325–1328, 1984.
- 34.A. Rabbani and colleagues, Department of surgery, School of Medicine, Medical sciences / University of Tehran, Tehran, Iran.