

## CRANIAL HYDATID CYST

Dr. Haitham Handhal\*

### OBJECT:

HYDATID disease is caused by infestation by larvae of the tapeworm *Echinococcus granulosus*. The disease is endemic in parts of the world in which sheep are raised. In 2 to 3% of cases CNS involvement occurs. Alveolar echinococcosis is caused by *Echinococcus multilocularis*. The foxes and dogs are the main host for the adult parasite known as *Echinococcus alveolaris*. Humans are affected either by direct contact with foxes or dogs or by contamination from plants or water. The liver is the primary organ affected by the disease. The clinical behavior of the disease is aggressive and is regarded as a potential malignancy.

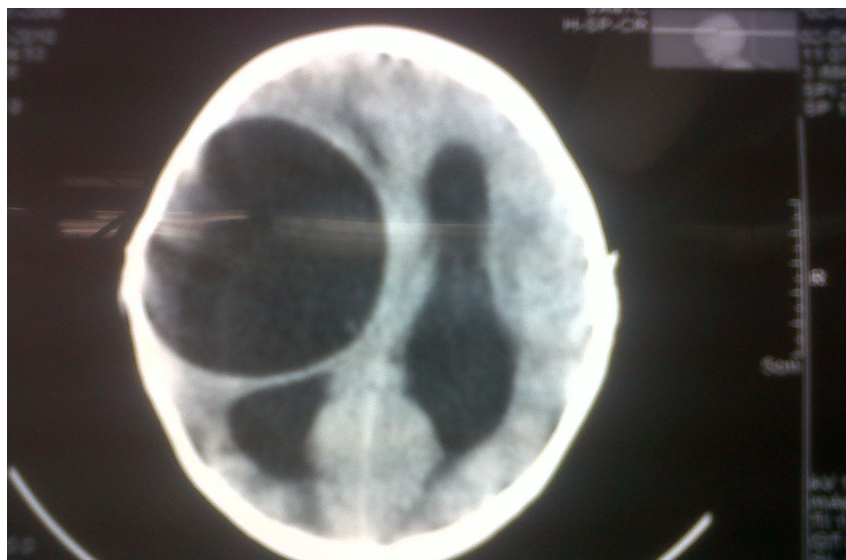Iraq is located in a geographic zone that is endemic for this parasite. Hydatid disease (*Echinococcus granulosus*) is endemic in the Middle East as well as other parts of the world, including India, Africa, South America, New Zealand, Australia, Turkey and Southern Europe. Infestation by hydatid disease in humans most commonly occurs in the liver (55-70%) followed by the lung (18-35%); the two organs can be affected simultaneously in about 5-13% of cases. Even though hydatid cysts can occur in any organ, it is very rare to see the disease in the regions reported in this paper. Considerable morbidity and even mortality can be caused by this benign disease, as seen in this report and the literature reviewed. The purpose of this paper is to emphasize the fact that this disease should be suspected in cystic lesions affecting any 'organ in the body, especially in endemic areas of the world.

### METHODS:

A prospective study on 5 cases of cranial hydatid cyst were operated upon during the period 2008-2011 and then followed up for at least 6 months post operatively.

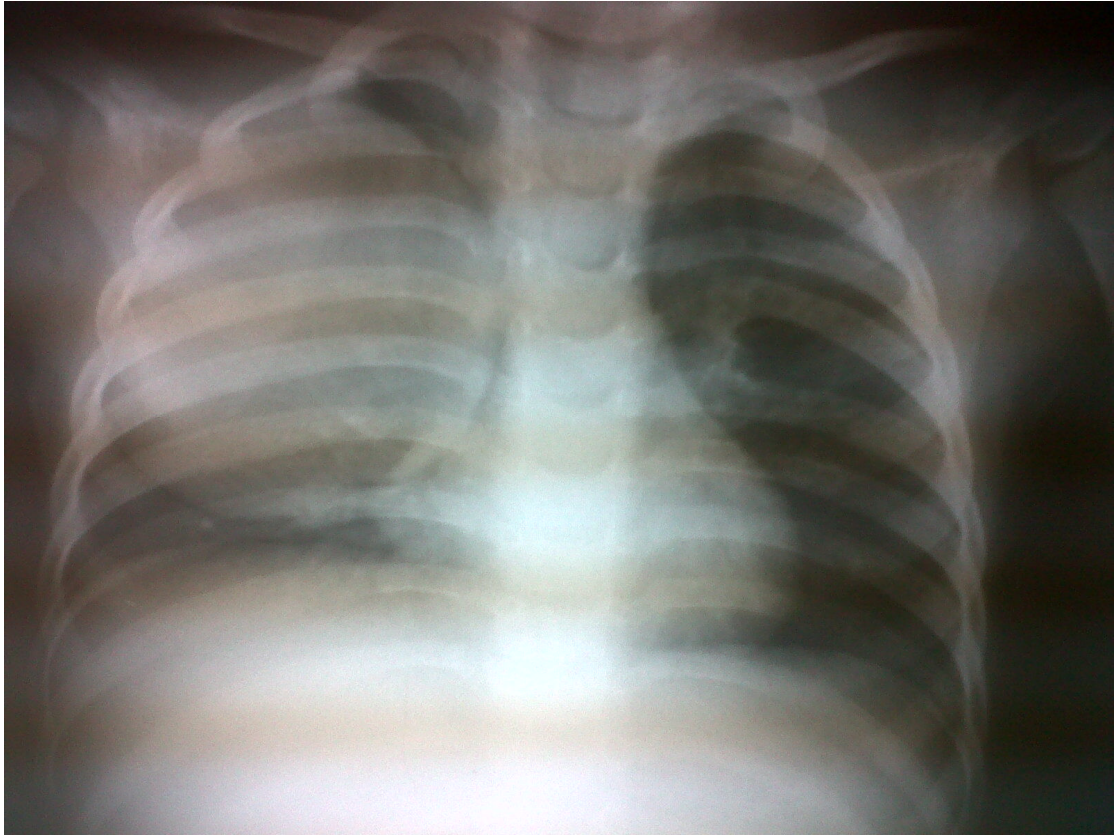
#### Case No.1

4 yr. old male referred to Al Hussein Teaching Hospital from Bint Al Huda Hospital complaining from Lt. sided weakness. Head CT scan reveals large Rt. fronto-temporo-parietal hydatid cyst.



## Cranial Hydatid Cyst

Pre-op. prep. Revealed that Rt. Lung hydatid cyst is also present when routine chest x-ray was done.

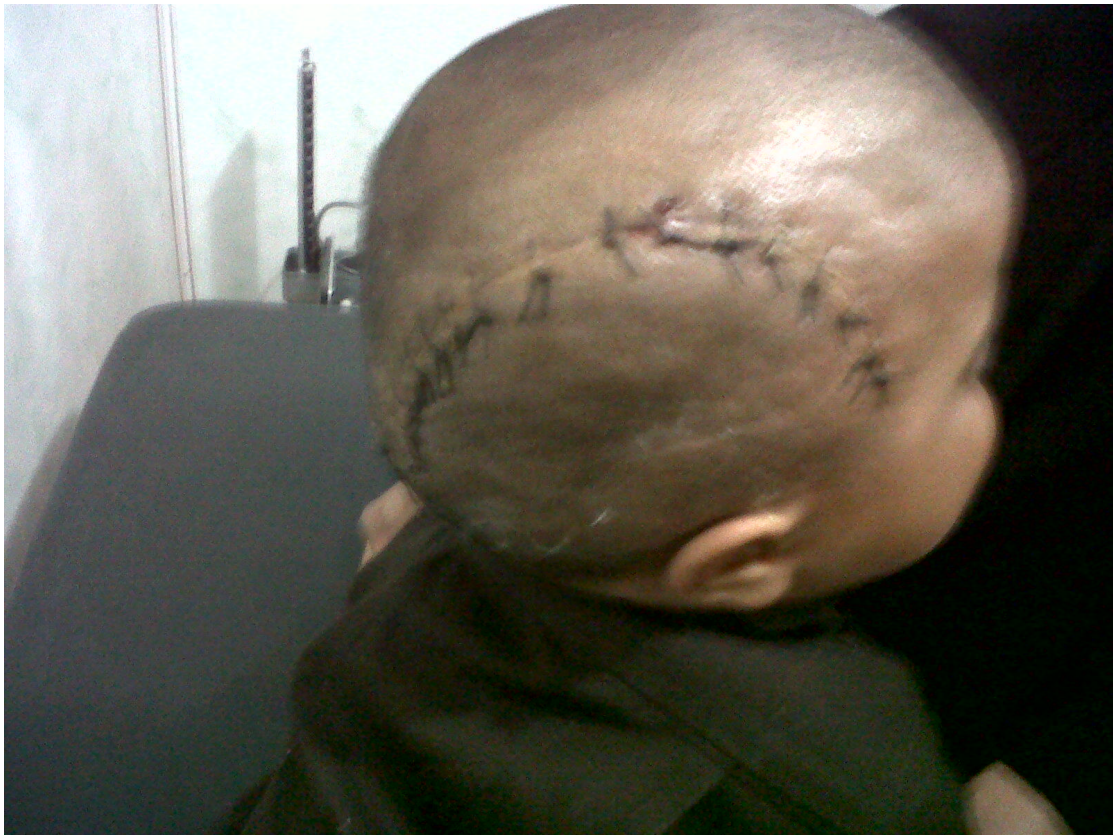

Abdominal U/S also revealed a liver hydatid cyst. The priority was to excise the pulmonary hydatid cyst, so the pt. was referred to a cardiothoracic surgeon who performed for him a Rt. Thoracotomy and total cyst excision was done. After that, the pt. was prepared for craniotomy, Rt. Fronto-temporo-parietal craniotomy was done and hydatid cyst was removed intact to prevent post op. recurrence.



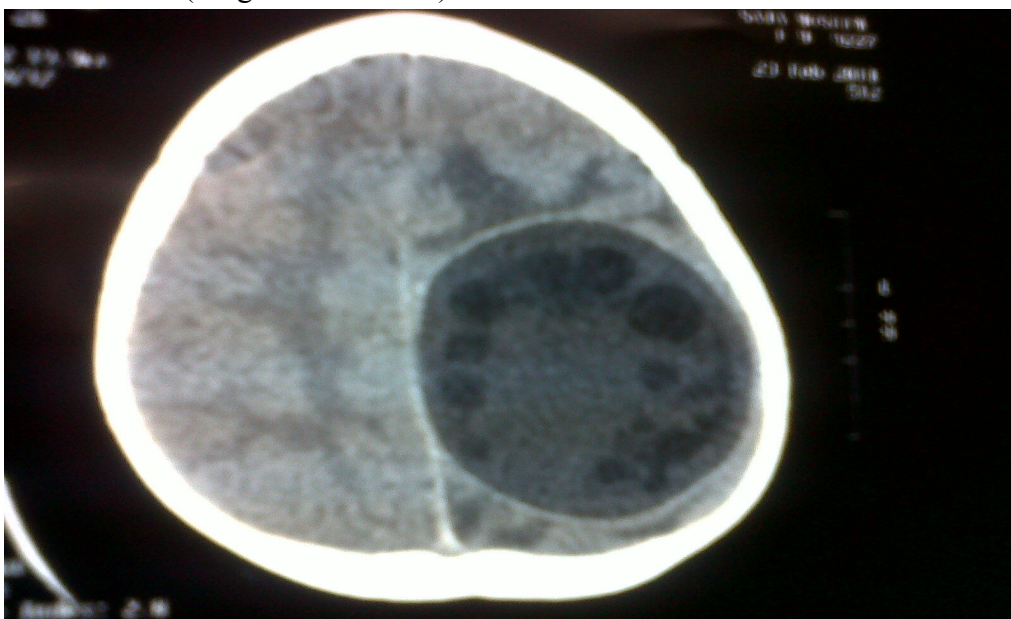

The post op. period was uneventful and the pt. was followed for 6 months later without any focal neurological deficit and then he was referred to a general surgeon to remove the liver hydatid cyst.



### Case No.2

10 yr. old female was referred from Al Shattra General Hospital to Al Hussein Teaching Hospital as a case of acute appendicitis, pt. was complaining from headache, nausea, vomiting, fever and abdominal pain. Examination revealed signs of meningeal irritation and Rt. Sided weakness. Head CT scan revealed large Lt. parietal brain hydatid cyst with signs of rupture and infection ( ring enhancement ).

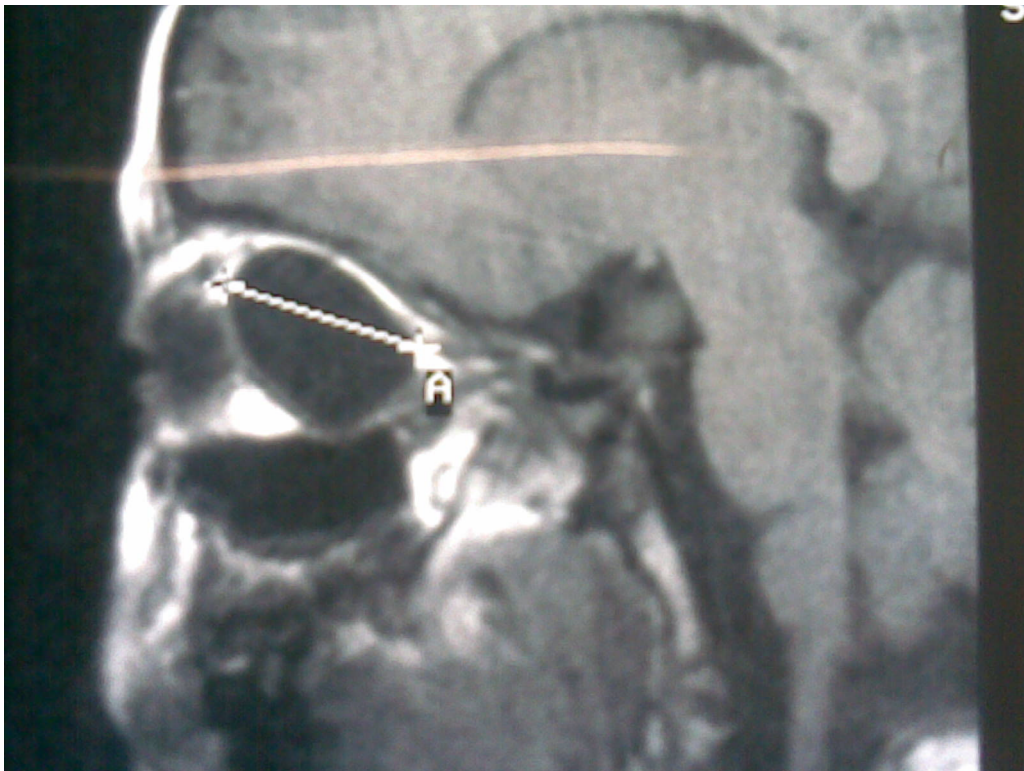

## Cranial Hydatid Cyst

Lt. parietal craniotomy was done for her, ruptured infected hydatid cyst was removed completely. Pt. developed post op. meningitis and further complicated by post meningitic hydrocephalus. Rt. Ext. Ventricular drain was seated for 14 days and then replaced by Rt. Ventriculo-Peritoneal shunt.

### Case No.3:

5 yr. old Iraqi child with sever orbital pain for 4 month duration with gradual displacement of his right eye( proptosis). The right pupil was normal reacting to light, the sclera was congested, the 2 fundi were clear. MRI of the brain showed cystic lesion in the Rt. intraorbital region, the lesion was medially situated. Exploration through right frontal craniotomy, orbital roof was very thin and easily opened. Orbital fascia is opened, orbital fat was delivered, and the cyst was very difficult to remove without rupture but was removed completely and successfully. Postoperatively, the patient was put on medical treatment and was discharged in a satisfactory condition.



## RESULTS:

5 cases of intracranial hydatid cysts managed at the Division of Neurosurgery between 2008-2011. The average age of presentation was 9.4 years. Four patients (80%) were in the first decade of life. Main presentations were headache, vomiting, blurring of vision and focal neurological deficit. Radiological investigation included computerized tomography (CT) and magnetic resonance (MR). 1 patient had multiple hydatid cysts(brain, lung and liver).

1 patient had cyst in the orbit. The commonest location was in the parietal lobe (4 cases). Total excision of the cyst was done in all cases. Recurrence was not seen in all cases in spite of rupture of the cyst in 2 cases. One of the cases who has ruptured infected hydatid cyst was

complicated by post op. meningitis and was treated by antibiotics for 14 days but it was further complicated by post meningitic hydrocephalus which was treated by ext. ventricular drain for 14 days. After that EVD was replaced by Ventriculo-peritoneal shunt.

## **CONCLUSION:**

1. Whenever you find cranial hydatid cyst you have to search for lung and liver hydatid cyst.
2. Ruptured cysts are associated with more complications.
3. Iraq is still an endemic area for hydatid cyst.
4. Any cystic lesion in Iraq should be considered as hydatid cyst until prove otherwise.
5. Children in the 1<sup>st</sup> decade of life are more vulnerable to hydatid cyst disease

## **REFERENCES:**

1. Sardana VR, Dharker SR, Mittal RS, et al. Multiple intracranial hydatid cyst. *Neurol India* 1991;39:205.
2. Onal C, Orhan B, Metis O, et al. Three unusual cases of intracranial hydatid cysts in paediatric age group. *Pediatr Neurosurg* 1997;26:208-13.
3. Jimenez-Mejias ME, Castillo-Ojed E, Cuello-Contrers JA, et al. Cerebral hydatidosis. Analysis of a series of 23 cases. *Med Clin (Barc)* 1991;97:125-32.
4. Lunardi P, Missori P, Di-Lorenzo ND, et al. Cerebral hydatidosis in childhood: a retrospective survey with emphasis on long term follow up. *Neurosurgery* 1991;29:515-8.
5. Balasubramaniam V, Ramanujam PB, Ramamurthi B, et al. Hydatid disease of the nervous system. *Neurol India* 1970;18:92-5.
6. Rivierez M, El-Azhari A, El-Tantaoui M, et al. Hydatid cyst of cavernous sinus (a case). *Neurochirurgie* 1992;38:46-9.
7. Sinav S, Demirci, Sinav B, et al. Primary intraocular hydatid cyst. *Acta Ophthalmol* 1991;69:802-4.