

ABDOMINAL CT FINDINGS IN PATIENT WITH ASCITES

Dr. Zaid Khdher Ahmmad, M.B.Ch.B –FICM (RD)*
Dr. Riyadh Adel Abdulazeez, M.B.Ch.B-FICMS(RD)**

ABSTRACT

Back ground and purposes:

Ascites is the collection of free fluid in the peritoneal cavity , normally the peritoneal cavity contain small amount of serous fluid for lubrication (less than 100 ml), free fluid exceeding this amount ,considered ascites .Ascites may result from variety of medical & surgical causes , clinically detectable ascites when its amount exceeding 1500 ml ,and when it is clinically important to confirm the presence of suspected ascites, ultrasonography (US) or computed tomography (CT) of abdomen is advisable , and the different CT signs of ascites depend on the amount and distribution of the ascetic fluid .

The Aim:

is to study the early and the late signs of ascites on abdominal CT , and to estimate the sensitivity of abdominal CT in diagnosing the cause of ascites

Patients and methods:

Eighty five patients of mean age 52.2 ± 13.8 years had ascites ,diagnosed either clinically or by US (all of them had an US examination), been referred for spiral CT-scan of abdomen as a further diagnostic step to confirm & identify the possible underlying cause of ascites (patients with medical causes of ascites “heart failure, renal failure ” had been excluded), abdominal spiral CT scan has been done using 8mm slice thickness (patient took oral diluted gastrografin 1.5-2hrs prior to the examination) & two sets of CT examinations had been done (without I.V & with I.V omnipaque “350mg/ml.

Results:

This study showed that CT was as sensitive as US in detection of ascites , and the different signs of ascites on CT images depended on the amount of ascetic fluid producing either (early)or(late) signs , the late signs were more frequently seen in this study .

This study also showed that CT was more useful in identifying the underlying cause of ascites (especially when related to the peritoneum , momentum or to the bowel) and the extent of the pathology and its proper staging .The frequency of the underlying causes of ascites were as follows: 62% due to underlying neoplasm ,15.5%due to underlying liver cirrhosis , 8.6% due to underlying inflammatory conditions & 3.4 % were post traumatic , however ,there were 10.3% of cases for which the CT scan didn't give us an idea about the underlying cause .

Conclusion:

CT was as sensitive as US in detection of ascites, and more useful in identifying the underlying cause of it , but still about 10% of patients requires further investigative steps .

Key words : Abdomen , ascites ; CT, spiral

* College of Medicine - Karbalah University

** College of Medicine - Thi-Qar University

INTRODUCTION

Ascites is the collection of free fluid in the peritoneal cavity ^(1,2). It is associated with profound changes in the splanchnic and systemic circulation, and with renal abnormalities ⁽³⁾. The normal peritoneal cavity contains only a small amount of serous fluid for lubrication - less than 100ml. Free fluid accumulation exceeding this amount is considered to be ascites. Peritoneal fluid moves along predictable pathways that are influenced by body habitus, gravity, intra-abdominal pressure gradients, adhesions, and mesenteric reflections and attachments ⁽⁴⁾. Ascites can be recognized clinically only when the amount of fluid present exceeds 1500 ml ^(5,6), even moderate amounts can be quite difficult to diagnose from plain film alone ⁽⁷⁾. When it is clinically important to confirm the presence of suspected ascites, ultrasonography (US) or computed tomography (CT) scanning of the abdomen is advisable ⁽⁶⁾. The pelvis is the most dependant part of the peritoneal cavity in both erect and supine positions and fluid preferentially accumulate there. As more fluid collects it passes into the paracolic gutters and on the right side reaches the subhepatic and subphrenic spaces ⁽⁷⁾. Pelvic fluid collections preferentially extend to the upper abdomen along the right paracolic gutter, as it is deeper than the left, and also because of anatomical barrier created by the phrenicocolic ligament ⁽⁴⁾. Peritoneal fluid in the paracolic gutters is distinguished from retroperitoneal fluid by the preservation of the retroperitoneal fat posterior to the ascending or descending colon, provided there is not a complete ascending or descending mesocolon. US may be more sensitive than CT in detecting small amount of ascites in the pelvis, particularly in thin patients ⁽⁴⁾. The CT attenuation values of

ascites are that of clear fluid, measuring around 0 Hounsfield unit (Hu) and ranges from 0 to +30 HU. CT attenuation values are not specific, although attenuation increases (dense ascites) with increasing protein contents as a general rule. Acute hemoperitoneum can be distinguished from other fluid collections by its high attenuation values (+30 Hu), but lower values may also be observed ^(4,8). Fat-fluid level sign on CT (shown by supine and decubitus scan) is pathognomonic of chylous ascites. On delayed contrast-enhanced CT, enhancement of intraperitoneal fluid due to increased vascular-peritoneal permeability may be seen which must be interpreted with caution ⁽⁴⁾. The earliest signs of ascites are fluid densities within the pelvis, visualized superiorly and laterally to the urinary bladder or rectal gas shadows. As more fluid accumulates it displaces the bowel out of the pelvis, when the fluid enters the paracolic gutters it displaces the colon medially from the flank fat stripes (thickening of peritoneal flank stripe). Fluid in the Morrison's pouch can obscure the fat interface with the posterior inferior border of the liver and results in failure to visualize its lower border. Ascitic fluid between the liver and the lateral abdominal wall slightly displacing the lateral margin of the liver may result in the visualization of a lucent band, the fluid being slightly less dense than the liver tissue (Hellmer's sign). Blood has a similar density to the liver, and a hemoperitoneum does not demonstrate this sign. In the presence of large ascites, the small bowel loops are usually centrally positioned within the abdomen. However, in patients with very severe ascites, bowel loops can be displaced from the central position in the absence of an intraperitoneal mass (separation of the loops), and general distention of the abdomen causing thinning of the flank stripes laterally (bulging flanks).

Large amount of fluid causes a generalized haze over the abdomen (gray abdomen), the scattered radiation produced results in poor visualization of the normal structures, such as psoas and renal outlines. Ascitic fluid under tension may result in an extraperitoneal mass effect. Peritoneal fluid that becomes loculated due to benign or malignant adhesions may appear as a cystic lesion with mass effect. In summary the abdominal CT findings according to the amount of ascites are:

Early signs (accumulation in the pelvis):
(1,7,9)

- ❖ Round central density in the pelvis + ill-defined urinary bladder top.
- ❖ Displacement of bowel loops out of the pelvis.
- ❖ Thickening of peritoneal flank stripe.
- ❖ Space between peritoneal fat and gut > 3 mm.

Late signs:

- ❖ Hellmer's sign.
- ❖ Medial displacement of ascending + descending colon.
- ❖ Obliteration of hepatic + splenic angles.
- ❖ Floating central loops.
- ❖ Separation of loops.
- ❖ Bulging flanks.
- ❖ Gray abdomen.
- ❖ Poor visualization of normal structures, such as psoas and renal outline.
- ❖ Extraperitoneal mass effect.

Causes of ascites (1,4,5,7,9,2,10)

- Portal hypertension
 - Cirrhosis
 - Fulminant hepatic failure
 - Hepatic out flow obstruction
 - . Congestive heart failure
 - . Constrictive / restrictive cardiomyopathy
 - . Budd-chiari syndrome- hepatic vein and / or inferior vena cava occlusion.

. Veno-occlusive diseases.

. Portal vein occlusion.

- Malignancy
 - Secondary carcinomatosis from ovary, stomach, colon commonly, and less commonly from pancreas, uterus and urinary bladder.
 - Primary mesotheliomas of the peritoneum.
 - Pseudomyxoma peritonei due to rupture of mucocele of appendix or ovarian cyst.
- Infection
 - Peritoneal tuberculosis.
 - Infectious peritonitis in HIV infected patients.
- Renal
 - Nephrotic syndrome
 - Nephrogenous in hemodialysis recipient
- Endocrine
 - Myxedema.
 - Meigs' syndrome.
 - Strauma ovarii
 - Ovarian hyperstimulation syndrome
- Pancreatic ascites associated with pancreatitis.
- Biliary leak
 - Previous surgery including laproscopic cholecystectomy.
 - trauma and percutaneous liver biopsy.
- Urine ascites
- Polyserositis e.g. systemic lupus erythromatosis and polyarteritis nodosa.
- Miscellaneous
 - Hypoproteinimea e.g. protein malnutrition and nephrotic syndrome.
 - Lymphatic obstruction-Filariasis, secondary carcinoma and lymphoma.
 - Trauma e.g. ruptured spleen and injured hollow viscous e.g. stomach, appendix and small intestine
- Mixed causes .

AIM OF THE STUDY:

This work was performed to:

1. Study the early and late diagnostic signs of ascites on abdominal CT scan.
2. Estimate the sensitivity of abdominal CT in diagnosing the cause of ascites.

PATIENTS & METHOD

Fifty eight adult patients from two participating hospital (Al-Kadymia teaching hospital and Al-Yarmook teaching hospital referred by physicians or surgeons for abdominal spiral CT as a further investigative step for patients who had been diagnosed as having ascites either clinically or by US examination, over the period from July 2003 to October 2004. In all referred cases the medical systemic causes of ascites such as (heart failure & renal failure) had been excluded depending on the clinical back ground of the patients & laboratory investigations. The CT examination had been done within 3-5 days after referral, and depending on the CT findings further steps in management followed, which included : either ascitic fluid aspirate , or fine needle asperation (FNA) cytology in cases where CT revealed an abnormal mass, or till the surgical exploration for the pathology that had been revealed by CT , these follow up steps were used to document the value of CT in diagnosing and identifying the underlying cause of ascites.

Spiral CT examination:

Abdominal spiral CT was performed using Somatom plus 4 unit (Siemens medical system); the CT examination was as follow:

- 1- All patients were examined in supine position, in
 cranio-caudal direction.
- 2- The CT protocols :
 - Slice thickness of 8mm
 - KVp 120-140

- MA 100-200

Two sets of contrast enhanced CT was done, the first 1.5-2 hours after taking oral diluted gasrografin and the second set of the examination after administering intravenous ionic contrast media (100-120ml omnipaque 350 mg/l), which was injected manually through an IV line and the CT images were iterpreted by two-specialist radiologist.

RESULTS

Fifty eight adult patients (35 men & 23 women); their ages ranged 19-69 years ,with mean of (52.2 +/- 13.8 years) were included in our study as shown in table (1). Table (2) representing the distribution of the detected ascitic patients on different diagnostic modalities , in which both the US and CT showed high sensitivity in detecting ascites (100% for each). The underlying cause of ascites and associated findings that were detected by abdominal CT-scan in comparison with US findings are shown in table (3) . In general the most common cause of ascites in patients referred for CT-scan in this study was malignancy 62%(figures 2,3,5,6) and the least common cause was post traumatic representing 3.4%. Among the malignant causes colorectal masses were the commonest cause representing 32.8% from the total number of patients . All the cases of secondary liver metastasis and peritoneal carcinomatosis were associated with underlying primary malignancy detected on CT (figures 3&5) , but there were 6 patients representing 10.3% for whom no underlying cause for ascites could be detected , on follow up FNA cytology was done for them , 3 of them diagnosed as peritoneal tuberculosis , CT findings suggests peritoneal tuberculosis in one of them (figure 9), the other 3 cases were post operative ascites due to previous surgical

exploration , in whom the referring surgeons decided CT-scan of the abdomen after few days of abdominal exploration to exclude continuous leak from abdominal viscous or loculated collection , the CT- scan found no other findings rather than ascites.

There are different CT diagnostic signs of ascites as shown in table (4) , which showed that the late signs were more frequently seen than the early signs , the most frequent CT signs in ascites were Hellmer's sign (figures 2,3) & displacement of ascending and descending colon (figures 6,7) , each account for 68.9% . We can see also that early signs such as (increase space between peritoneal fat and gut more than 3mm) were not observed in our study .the prevalence of the results in this table are overlapping because more than one sign (including early and late signs)was detected in each patient .

DISCUSSION

In this study, most of our patients were within the age group (40-60years), because the most common cause of ascites detected was malignancy (whether primary or secondary),which showed high incidence at this age group. The sensitivity of detecting ascites depending on the clinical background as obtained from patients data in this study was 86.2% , this agrees with Cattau et al (1982), were they concluded that the sensitivity & specificity of the physical examination maneuvers ranged from 50% - 94% and 29% -82% ,respectively ,and the overall accuracy was only 58% and also concluded that routine physical examination had limitations in the precise diagnosis of equivocal ascites⁽¹¹⁾. The sensitivity of US and CT in detecting ascites in this study was 100% for each modality .US is the primary imaging modality in patients with Ascites because it is reliable , non invasive method and also useful in detecting solid masses within the fluid ^(1,6) , however US has

limitations in identifying the underlying cause , or associated findings ,whether technical limitations like in obesity , or inability to visualize the central mesentery, peritoneal seedlings or peritoneal carcinomatosis^(4,5) . US was not able to detect any case of peritoneal carcinomatosis, while CT detected all the 8 cases; Walkey et al (1988), reported that ascites was the most common CT findings in patients with peritoneal carcinomatosis⁽¹²⁾.For that reason CT is superior to US in detecting underlying cause of ascites ,as sectional images obtained added further information regarding the extent and staging of the disease ^(13, 14) . For the other causes, like colorectal masses, CT detected 19 cases (32.8% of the total patients) , while only 12 cases (20.7% of the total patient) , were detected by US, However , US could detect all ovarian masses (11cases in this study) which was equal to CT, this agrees with Sanders et al (1993), were they found that there was no significant difference in the ability of both CT and US to identify pelvic masses , or to predict disease extent ,the reported sensitivity in detecting pelvic masses was 96% and 91% for each CT and US respectively ⁽¹⁵⁾. Congestive heart failure and liver cirrhosis are the commonest causes of ascites ^(1,5,16,17) ,however, in our study all cases of congestive heart failure were excluded ,while clinically equivocal cases of liver cirrhosis were referred for further assessment by abdominal CT (figure8) . The commonest cause of ascites regarding further assessment by abdominal CT in our study was malignancy representing 62% of the total patients , among which colorectal and ovarian masses were the commonest ,representing 32.8% and 18.9% respectively ; and the least common cause was post traumatic representing 3.4% of the total patients , this agrees with what was reported by Jolles &

Abdominal Ct Findings In Patient With Ascites

Coulam (table 5) were they showed approximate results 72% & 2% for malignancy & post traumatic ascites respectively⁽¹⁸⁾. In this study six cases (10.3% of the total patients) no underlying cause was detected, this also agrees with Jolles et al(1980)⁽¹⁸⁾ (excluding three post operative cases), the remaining were due to peritoneal tuberculosis as proved on follow up (figure9). The observation of an irregular soft tissue densities on omental areas or low density masses surrounded by thick solid rim or disorganized appearance of soft tissue densities or fluid & bowel loops forming poorly defined masses of low densities & with multilocular appearance after contrast enhancement, even possibly high density ascites, all are non specific signs, and wide differential diagnosis has to be excluded like lymphoma peritoneal carcinomatosis, peritonitis & peritoneal mesothelioma^(19,20). Most of the diagnostic signs of ascites detected on abdominal CT in our study were late signs (Hellemer and medial displacement of the ascending and descending colon) in which they

represented 68.9% for each sign, this was because that most of the referred cases had moderate to severe ascites which was diagnosed clinically or by US, where CT-scan of the abdomen was requested to identify the underlying cause, also may be due to that medical causes for ascites had been excluded in this study.

CONCLUSION

The appearances of different signs of ascites on the CT images depends on the amount and distribution of the ascitic fluid within the peritoneal cavity, the late signs (Hellemer's sign and medial displacement of the ascending and descending colon sign) were seen more frequently than the early signs. CT-scan was as sensitive as US in the detection of ascites, the study also found that CT was more sensitive than US in the detection of the underlying cause and associated findings in ascitic patients (especially in peritoneal and bowel related pathologies).

TABLES

Table (1): age & gender distribution of the patients		
Age range (years)	Number of female patients	Number of male patients
<19	0	1
20-39	3	9
40-59	14	13
>60	6	12
	23	35

Table (2): distribution of detected ascitic patients on different diagnostic modalities.

Total No. of Cases	No. of ascitic patients detected on clinical background	No. of ascitic Patients detected on US	No. of ascitic Patients detected on CT
58	50	58	58

Abdominal Ct Findings In Patient With Ascites

Table (3): associated findings & underlying cause on CT and US in patients with ascites:

Associated findings	Cases detected on US	Cases detected on CT
Neoplasm		
• Colorectal masses		19 (32.8%)
• liver		
• Gastric masses	12(20.7%)	1 (1.7%)
• Ovarian masses		5 (8.6 %)
Peritoneal carcinomatosis	1 (1.7%)	11 (18.9 %)
	1(1.7 %)	
	11 (18.9 %)	8 (13.8 %)
		(4 cases associated with colonic, 1 with gastric and 3 with ovarian masses)
Liver metastases	0 (0 %)	8 (13.8 %)
		(4 cases with colorectal
	7(12.1%)	
	(3cases with colorectal	3 with ovarian and
	3 with ovarian and 1 with gastric masses)	1 with gastric masses)
Cirrhosis		
Inflammatory (all cases were pancreatitis)	7 (12.1 %)	9 (15.5 %)
	3 (5.2 %)	5 (8.6 %)
pleural effusion		
		2 (3.4 %) (1 case associated with ovarian and 1 with pancreatitis)
	1 (1.7 %)	
para-aortic lymph nodes enlargement		
	4 (6.9 %)	6 (10.3 %)
	(3 cases associated with colorectal & 1 with gastric mass)	(3 cases were associated with colorectal masses and 3 with gastric masses)
		2 (3.4 %)
		(rupture spleen and leaking aortic aneurysm)
post- traumatic		6 (10.3 %)
		(3 of them were postoperative, and 3 were tuberculosis on follow up)
unknown *	1 (1.7 %)	
	(rupture spleen)	
	13 (22.4 %)	

* means no associated findings were detected

Table (4): diagnostic signs of ascites detected on abdominal CT

Signs	No. of cases
A-Early signs	
Round central density in the pelvis + ill defined bladder top	10 17.2%
Thickening of peritoneal flank strip	6 10.3%
Space between peritoneal fat and gut > 3mm	0 0%
B- Late signs	
Hellemer sign (medial displacement of lateral liver margin)	40 68.9%
Medial displacement of ascending and descending colon	40 68.9%
Obliteration of hepatic and splenic angles	34 58.6%
Bulging flanks	12 20.6%
Gray abdomen	10 17.2%
Floating centralized loops	12 20.6%
Separation of loops	8 13.8%

Table (5): associated abdominal CT findings in current and previous study

Associated findings	Current study No. of patients(58)	H.Jolles and CM. Coulam Study No. of cases(43)
Neoplasm	62.1 %	72%
Inflammatory	8.6 %	10%
Cirrhosis	15.5 %	8%
Trauma	3.4 %	2%
unknown	10.3%	4%

FIGURES

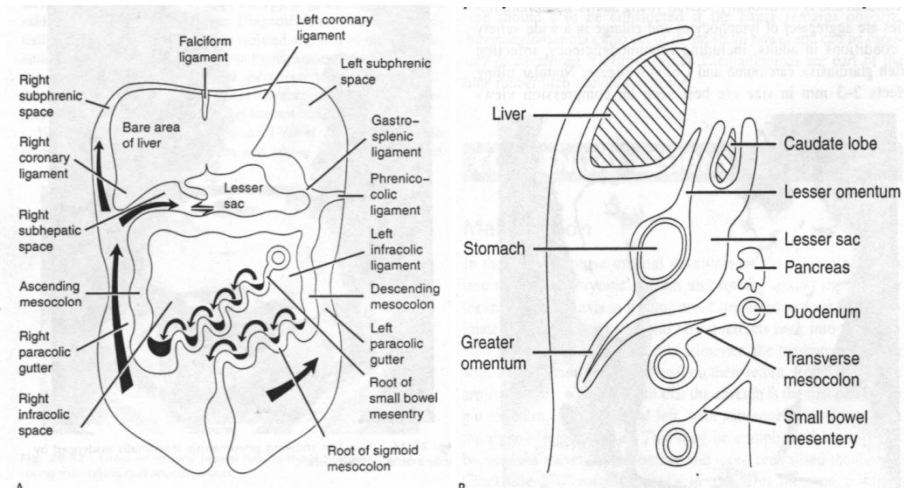


Figure 1: shows peritoneal attachments and spaces ,viewed from front and side , and also shows the likely pathways for the the spread of pathological processes.

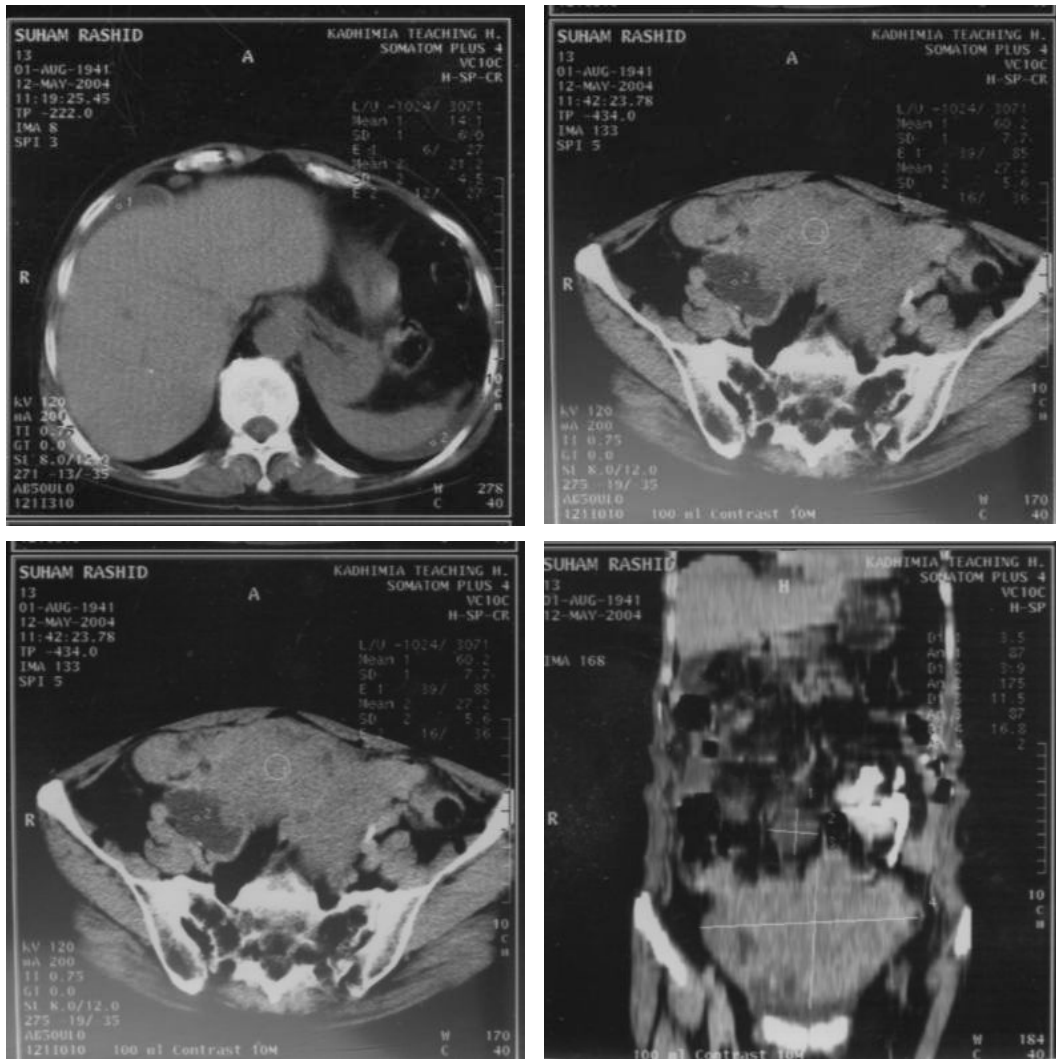


Figure 2: spiral CT-scan of the abdomen of 64 years old female with Ovarian tumor & ascites (see the Hellemer's sign & the early Sign of ill-defined bladder top on the reconstruction image)

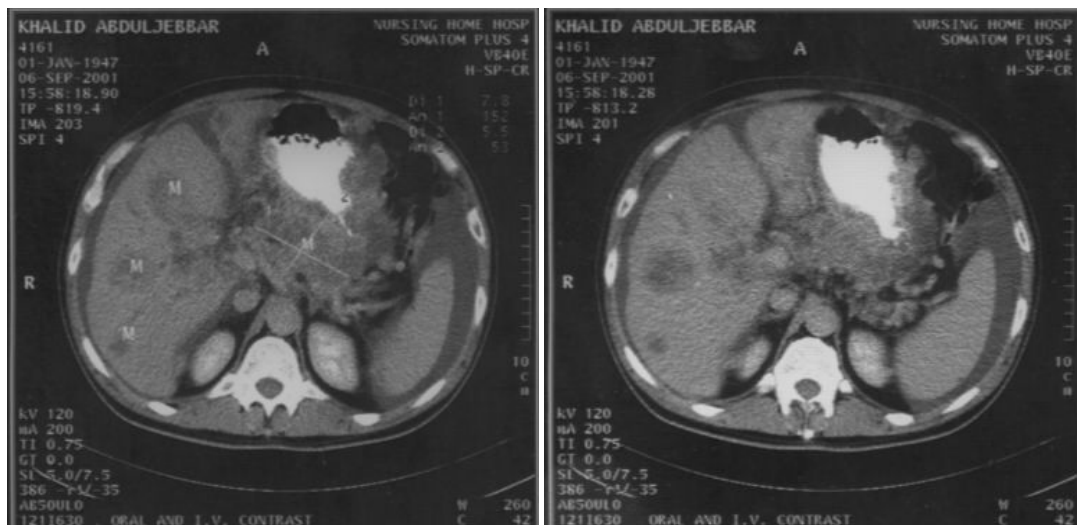


Figure3: this is spiral CT scan of a 58 yr. old male with large gastric tumor with liver metastasis & ascites (obliteration of the hepatic & splenic angles sign, +ve Hellmer's sign)

Abdominal Ct Findings In Patient With Ascites

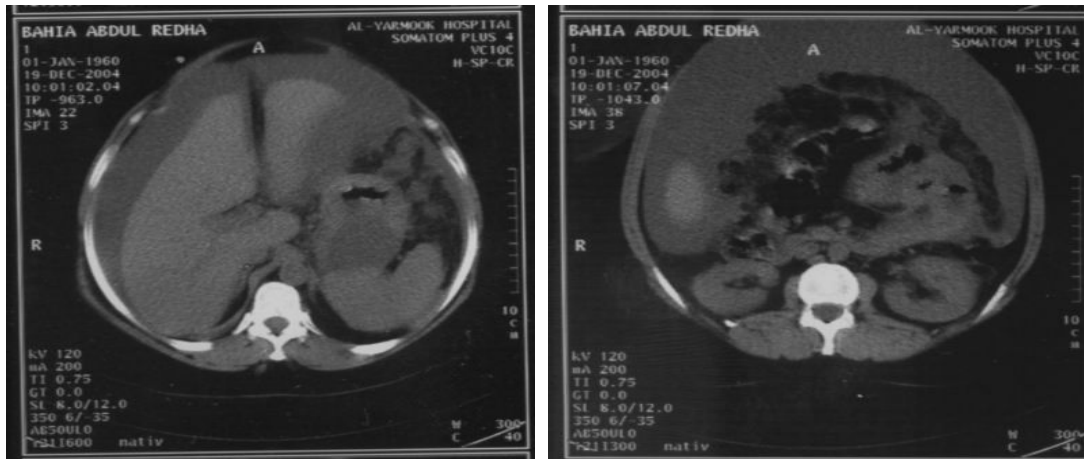


Figure 4: spiral CT scan of 45 years old female with ovarian CA, Showing sever ascites showing two of the late sign (obliteration of the hepatic angles & floating centralized loops)

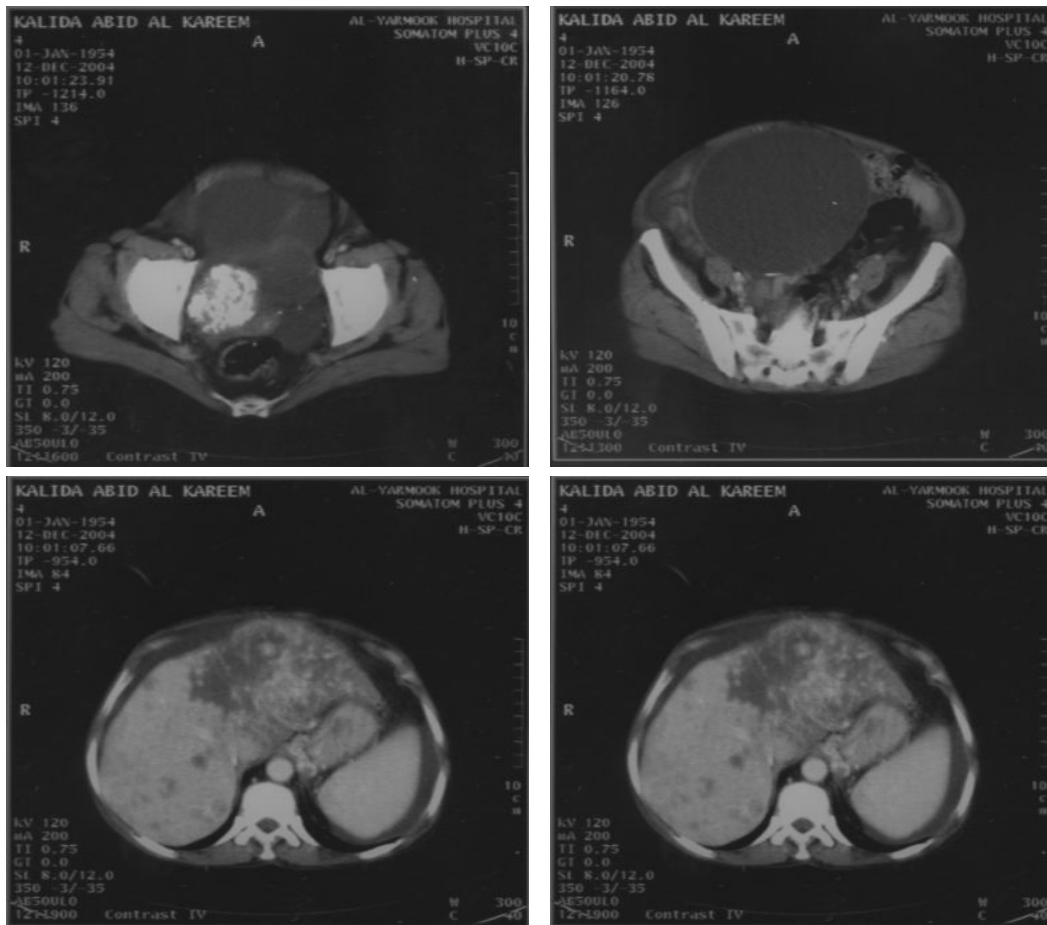


Figure 5: spiral CT scan of 51yr old female with cystic ovarian tumor & Liver metastasis, with ascites (late sign: obliteration of the hepatic & splenic angles).

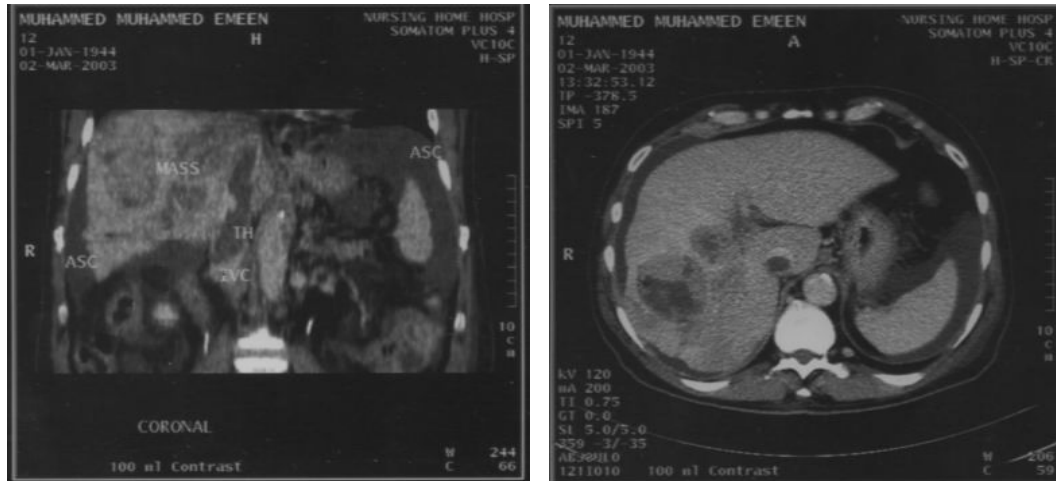


Figure 6: spiral CT scan of 61 years old male with hepatic tumor and ascites (late sign of ascites: obliteration of hepatic & splenic angles).

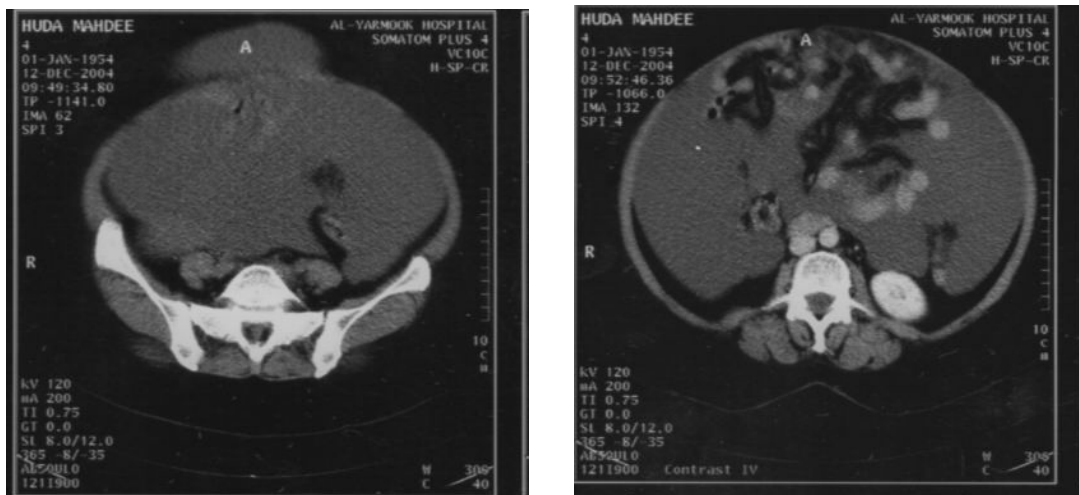


Figure 7: 61 years old female had previous operation for ovarian CA, presented with very sever ascites (late signs: gray abdomen sign, floating centralized loops & separation of the loops).

Abdominal Ct Findings In Patient With Ascites

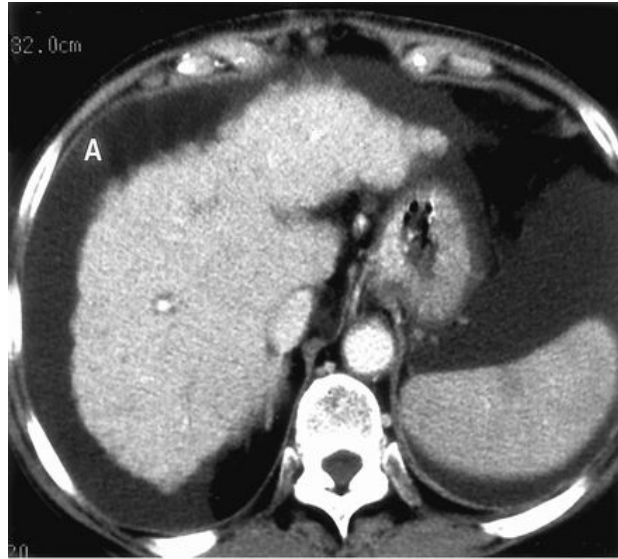


Figure 8: spiral CT- scan of patient with liver cirrhosis, with ascites (late sign: obliteration of the hepatic & splenic angles)

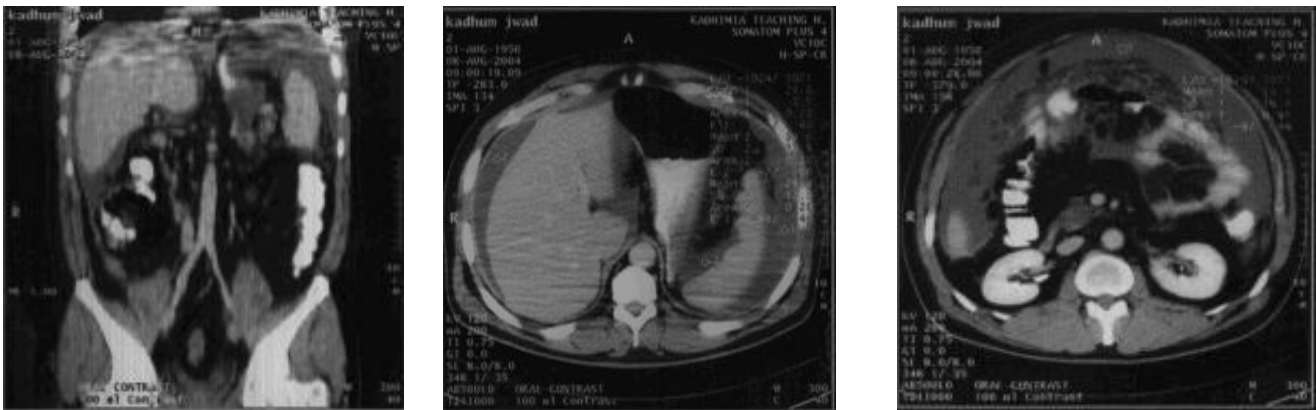

Figure 9: CT scan of the abdomen who had unexplained ascites , for which CT gave the suggestion of TB peritonitis (dense ascites ,thickened omentum & adherent bowel loops), follow up with ascitic fluid analysis confirm the CT suggestion .

REFERENCES

- 1-Krishna K V. Gastroenterology in: A short text book of medicine, 1st edition . New Delhi :Jaypee Brothers. 1987; 399-404.
- 2- Jeong YY. Ascites –review. Radiographics 2000 ; 20 : 1445-1470.
- 3 - Cardenas A, R Bataller, V Arroyo. Mechanism of ascites formation. Clin Liver Dis 2000; 4 :447-465.
- 4-Field S. . The abdomen In: Grainger R.G. , Allison D.J. . Grainger &Allison’s diagnostic radiology: A text book of medical imaging . 3^{ed}edition.USA:Churchil Livingstone 1999 : 902 .
- 5 - Harding A J, Charles V. peritonium. in: Bailey & love’s short practice of surgery, 20th. England : ELBS. 1989; 1016-1017.
- 6-Fallon M.B. ,Mcguire B.M. ,Abrams G.A. , Arguedas M.R. .Chirrhosis of the liver and its complication In : Andreoli T.E. , Carpentar C.C.J, Griggs R.C. , Loscalzo J. . CECIL essentials of medicine . 5th edition . philadelphia ,pensalvania : W.B. Saunders company 2001 :390-391 .
- 7 -Halligan S . The small bowel and periyoneal cavity. In Sutton D, eds. Text book of radiology and imaging, 17th ed. London: churchill livingstone, 2003; 633-634.
- 8- Gayer G, et al .Dense ascites: CT manifestation & clinical implications. Emergency Radiology 2004; 10:162-267.
- 9- Dahnert W . gastrointistinal tract . In: Radiology review manual ,4th ed. India: William’s & Wilkin’s. 1999: 618.
- 10 - Shi Y, Hao M, Ding Z. Study on ascites of ovarian cancer . Zhonghua Fu Chan Ke Za Zhi 2000; 35 :551-553.
- 11- Cattau E, et al .The accuracy of physical examination in the diagnosis of suspected ascites . JAMA 1982;247: 26.
- 12- Walkey MM, et al. CT manifestation of peritoneal carcinomatosis . American Journal of Roentgenology 1988;150: 1035-1041.
- 13- Thoeni RF. The role of imaging in patient with ascites. American Journal of Roentgenology 1995; 165: 16-18.
- 14- Halvorsen RA , et al. CT differentiation of pleural effusion from ascites :an evaluation of four signs using blinded analysis of 52 cases . Invest Radiology 1986; 21: 191-395.
- 15- Sanders RC, et al. Aprospective study of CT& US in detection and staging of pelvic masses . Radiology 1993; 146: 439-442.
- 16- Christopher R W, Bouchier A D. Diseases of the liver and biliary system. In : Davidson’s principles & practice of medicine, 16thed . London : Churchil Livingston, 2002 ; 527-529.
- 17- Blachar A, et al. Primary biliary cirrhosis: clinical ,pathological and helical CT findings in 53 patients . Radiographics 2002; 22: 1369-1384.
- 18- Jolles H , Coulam CM . CT of ascites: differential Diagnosis. American Journal of Roentgenology 1980; 135: 315-322.
- 19- Epstein BM, Mann J H . CT of abdominal tuberculosis . American Journal of Roentgenology 1982; 139: 861-866.
- 20- Ha HK, et al .CT differentiation of tuberculous peritonitis & peritoneal carcinomatosis .American Journal of Roentgenology 1996;167:743-748.

مشاهدات المفراس لمرضى استسقاء البطن

د/زيد خضر احمد* -

د/رياض عادل جاعد عبد العزيز الخزاعي**

استسقاء البطن يعرف بانه تجمع السوائل الغير مقيدة داخل التجويف البطني . لكي يمكن معرفة سريريا استسقاء البطن يجب ان يتجاوز ال ١٥٠٠ مل . ولكي يكون بمقدورنا ان نحدده باقل من هذه الكمية يجب ان تعتمد على فحص الامواج فوق الصوتية او المفراس

الغاية من هذه الدراسة:

هي معرفة العلامات الابدائية والمتاخرة لتشخيص استسقاء البطن بواسطة المفراس ومدى تحسس هذا الجهاز للكشف عن الاسباب المؤدية لاستسقاء البطن.

ثمانى وخمسون مريضا بمعدل عمر ٥٢,٢ +/- سنة كانوا عينة هذه الدراسة جمعهم مصابون باستسقاء البطن شخوصا سريريا وبواسطة الامواج فوق الصوتية . تم فحص هؤلاء بواسطة المفراس الحلزوني لتأكيد الحالة ولمعرفة الاسباب المؤدية لاستسقاء البطن . (تم استبعاد حالات الفشل الكلوي وعجز القلب) .

اجري فحص المفراس باستخدام ٨ ملم سمك شريحة بعد شرب الصبغة الملونة وبمرحلتين بدون الصبغة الوريدية وبعد اعطاء الصبغة الوريدية.

النتائج :

اثبتت الدراسة بان المفراس حساس جدا في تشخيص استسقاء البطن بدرجة مماثلة لفحص الامواج الصوتية كما ان العلامات المتاخرة في فحص استسقاء البطن بواسطة المفراس هي اكثر ظهورا في هذه الدراسة من العلامات الاولية . اثبتت الدراسة ايضا بان المفراس اكثر دقة من فحص الامواج الصوتية في معرفة الاسباب المؤدية لاستسقاء البطن وخاصة في مايتعلق بالغشاء البريتوني والامعاء . ٦٢% من اسباب استسقاء البطن هو من اصل سرطاني اما الاسباب الاخرى فانت بنسب اقل من ذلك . كما اثبتت الدراسة بان هناك حالات لاستسقاء البطن تقدر بنسبة ١٠,٣ % لايمكن الوصول بها الى تشخيص بواسطة المفراس الحلزوني اغلبها عقابيل عمليات جراحية او باثر تدريجي.

الاستنتاجات :

المفراس الحلزوني موازي بامعرفة استسقاء البطن اسوة بفحص الامواج الصوتية ولكن المفراس اكثر دقة بمعرفة الاسباب المؤدية له بالمقارنة .

* بورداشعة تشخيصية- كلية الطب/جامعة كربلاء

** بورداشعة تشخيصية- كلية الطب/جامعة ذي قار