

REDUCTION OF INFERIOR TURBINATE BY RADIOFREQUENCY

Dr.Shamil A. Hilal M.B.Ch.B – F.I.C.M.S. (ORL)*

ABSTRACT:

Objective : A prospective study was done at the period of 3rd July2009 - 4th Seb.2010 to see the effectiveness of radiofrequency in inferior turbinate reduction regarding nasal obstruction,morning sneezing , snoring, headache and nasal discharge.

Method : Thirty-seven patients had been underwent radiofrequency turbinate reduction under local anesthesia and follow up them regarding their complaints.

Results : We found that radiofrequency inferior turbinate reduction is very simple, effective, and relatively complication free as out patient procedure.

Conclusion : Radiofrequency for inferior turbinate reduction can be held as outpatient procedure with minimal time & relatively simple cost and give the same results as other procedure that held to reduce the inferior turbinate bulk . So it is preferable over them when the equipments are available.

Keywords: radiofrequency, inferior turbinate reduction,

INTRODUCTION

There are many potential causes for nasal obstruction. Some of the most common causes are nasal allergies, deviation of the nasal septum, sinusitis and rhinorria. The nasal passages can also be obstructed by enlarged inferior turbinate which can impair normal breathing, causing mouth breathing. Enlarged turbinate may be treated with medicines (intranasal sprays and drops) or surgical intervention (SMD , turbinopalsaty , turbinectomy , ..etc) may be considered especially if turbinate hypertrophy is chronic when the bone and /or mucosa may be enlarged 1.

Turbinate hypertrophy mainly affecting the life quality of the patient by causing disturbance of nasal airflow , resulting in symptom of nasal obstruction throughout the day, as well as during sleep which can impair normal breathing, forcing patients to breathe through the mouth and often

affecting their daily activities.

Radiofrequency turbinate reduction (RFTR) is a minimally invasive surgical option that can reduce tissue volume in a precise, targeted manner. This technique uses radiofrequency to create fibrosis within the sub mucosal tissue of the turbinate, reducing tissue volume with minimal impact on surrounding tissues. 2 Radiofrequency turbinate reduction differs fundamentally from traditional methods by using low-power radiofrequency energy to provide a relatively quick and painless procedure for tissue coagulation.

Radiofrequency inferior turbinate reduction can be used in patients with the following conditions: 2,3,4,5

1. Nasal congestion and rhinorrhea associated with inferior turbinate mucosal hypertrophy.
2. Nasal congestion with inferior turbinate

* Lecturer Otolaryngologist, College of Medicine, Thi-Qar University

Reduction Of Inferior Turbinate By Radiofrequency

mucosal hypertrophy with a mildly deviated septum.

3. Sleep apnea with increased nasal resistance and difficulty wearing a nasal CPAP mask.

4. Inferior turbinate mucosal hypertrophy undergoing septoplasty, rhinoplasty, or endoscopic sinus surgery.

5. Rhinitis medicamentosa requiring adjunctive treatment.

AIM OF THE STUDY:

The aim of this study is to determine the efficacy of Inferior Turbinate Reduction by Radiofrequency and also to search for any adverse side effect or complication.

MATERIAL AND METHOD

A thirty-seven patients , 30 male and 7 female , aged 16-60 years , all have symptoms and signs of non allergic, non infective nasal obstruction associated with inferior turbinate hypertrophy refractory to medical therapy from relevant history and clinical examination included: rhinoscopy, subjective visual analogue scale (VAS) score " in which a patient described his symptoms in points from 0 to 10 , e.g. 10 (always very good nasal airflow) to 0 (always total obstruction) " , any patient with allergy, chronic infection or sever septal deviation was excluded.

Under local anesthesia in out patient clinic by spray of 10% xylocain then local infiltration of dental formula 2% Mepovacaine HCl +Levonordefrin 1:20000 in the anterior part of inferior turbinate by dental syringe.

By using bipolar SMD probe of radiofrequency surgical system in 2 or more sites, 100% intensity, for 10 seconds each.

Patient satisfaction was calculated as score from 1-10 regarding nasal obstruction, morning sneezing, discharge, headache, and snoring. The clinical assessment was before radiofrequency-turbinate reduction, within 2 to 3 months and 9 to 12 months after this therapy.

RESULTS:

The results was in means regarding nasal obstruction, morning sneezing, nasal discharge , headache and snoring 2-3 months & 9-13 months later as shown in following diagrams:

DISCUSSION:

The advantage of radiofrequency volumetric tissue reduction (RFVTR) over electrocautery for turbinate hypertrophy is that the former can be performed as an office procedure with local anesthesia, whereas the latter is done in an outpatient surgical center under general anesthesia⁶.

The evidence supporting RFVTR for inferior turbinate reduction consists of prospective case series. However, there are no studies directly comparing RFVTR to electrocautery or cold knife surgery (which are the established alternative methods of inferior turbinate reduction) . In addition, there are no reports of the long-term durability of inferior turbinate reduction with RFVTR. In a review of the literature on radiofrequency ablation for sleep disordered breathing, Massod and Phillips (2001) concluded that application of RFVTR to the tongue and turbinate has not been studied thoroughly enough to assess its efficacy at present⁷.

Recent studies suggest that radiofrequency tissue ablation may be effective in treating chronic nasal obstruction and refractory allergic rhinitis. In a prospective, randomized, double-blind, placebo-controlled clinical pilot study, Powell et al (2001) estimated the treatment effect of temperature-controlled radiofrequency (TCRF) reduction of turbinate hypertrophy in patients with sleep-disordered breathing⁸.

In a prospective, non-randomized study, Black et al (2002) evaluated the effectiveness and morbidity of bipolar radiofrequency thermal ablation of the inferior turbinate's in patients with nasal obstruction caused by turbinate hypertrophy (n = 20). The authors concluded that the bipolar radiofrequency thermal ablation of

inferior turbinate's is a promising option, for inferior turbinate hypertrophy⁹.

In a randomized controlled trial (n = 32), Nease and Krempf (2004) assessed the short-term (8 weeks and 6 months) effectiveness of RFVTR in treating nasal obstruction in subjects with inferior turbinate hypertrophy. These investigators concluded that RFVTR is an effective alternative for the treatment of patients with nasal obstruction due to inferior turbinate hypertrophy. However, this is the first randomized study that demonstrates that RFVTR is significantly better than placebo in treating nasal obstruction due to inferior turbinate hypertrophy. Its findings need to be

validated by future studies with larger sample size and longer follow-up¹⁰.

CONCLUSION:

We conclude that radiofrequency turbinate reduction is simple, easy, effective method also it can be done under local anesthesia with less complication than other traditional methods.

ACKNOWLEDGEMENT:

Dr.Rabee J. Al-Amar & Dr.Aws A. Hussona ,Specialist Otolaryngologists in Habbobi Hospital, Annassiriya for their kind help in all parts of this effort.

Figure (I) ; Clinical signs 2-3 months after intervention:

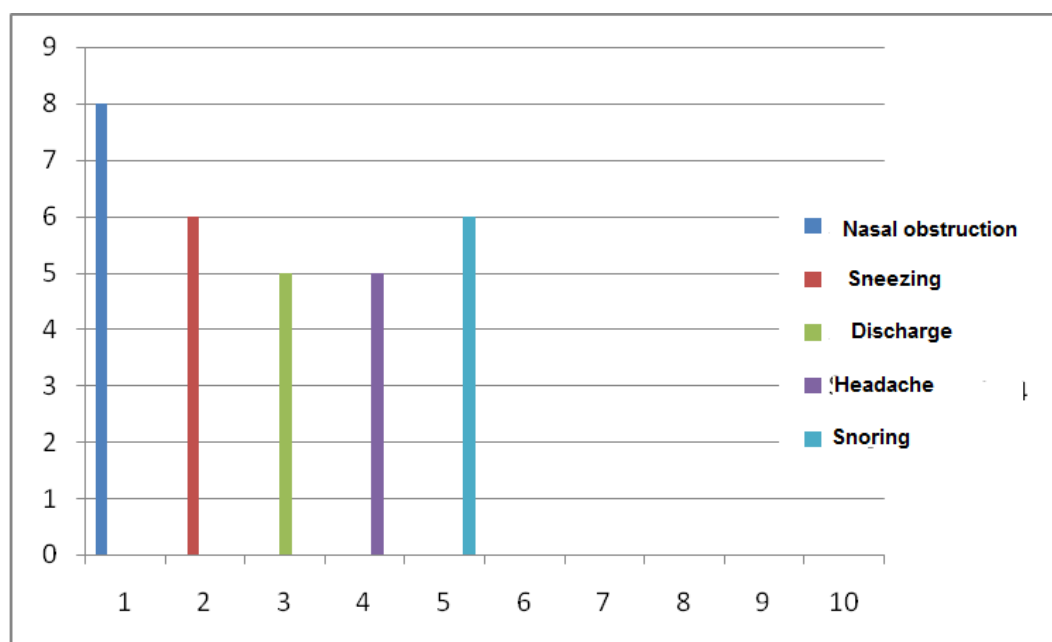
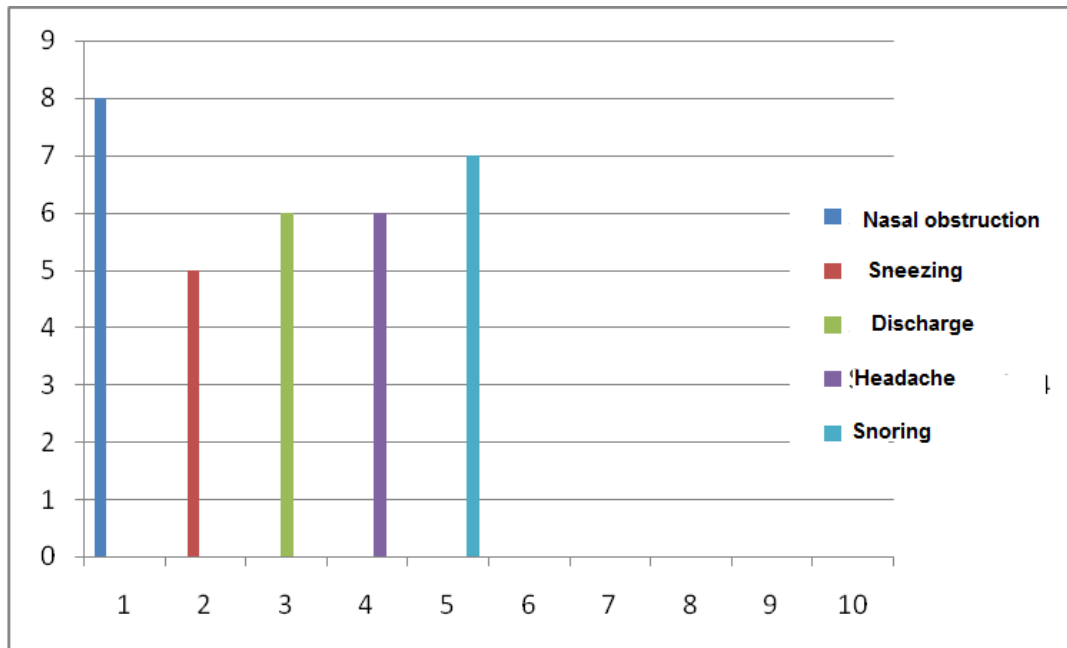


Figure (II) ; Clinical signs 9-13 months after intervention:

Reduction Of Inferior Turbinate By Radiofrequency



REFERENCES:

1. Ferris B, Mead J, Opie L (1964) Partitioning of respiratory flow resistance in human. *J Appl Physiol* 19:653–658.
2. Belachew Tessema and Seth M Brown . Radiofrequency Turbinate Reduction . e-medicine web site . Jul 28, 2009
3. Scott brown otolaryngology head and neck surgery vol 2 7th Ed. By Michel Gleeson.
4. Coste A, Yona L, Blumen M, et al. Radiofrequency is a safe and effective treatment of turbinate hypertrophy. *Laryngoscope*. May 2001; 111(5):894-9. [Medline].
5. Utley DS, Goode RL, Hakim I. Radiofrequency energy tissue ablation for the treatment of nasal obstruction secondary to turbinate hypertrophy. *Laryngoscope*. May 1999; 109(5):683-6. [Medline].
6. Porter MW, Hales NW, Nease CJ, Krempel GA. Long-term results of inferior turbinate hypertrophy with radiofrequency treatment: a new standard of care?. *Laryngoscope*. Apr 2006; 116(4):554-7. [Medline].
7. Yildirim B, Uysal IO, Polat C, Gok C. [The efficacy of radiofrequency ablation technique in patients with inferior turbinate hypertrophy]. *Kulak Burun Bogaz Ihtis Derg*. Mar-Apr 2008; 18(2):90-6. [Medline].
8. Somnus Medical Technologies, Inc. Turbinate Somnoplasty: Relief of Chronic Nasal Obstruction. PN 190-1003C. Sunnyvale, CA: Somnus; March 1999. Available at <http://www.somnoplasty.net/MDTrack/PDFs/turb.pdf>. Accessed January 18, 2001.
9. Masood A, Phillips B. Radiofrequency ablation for sleep-disordered breathing. *Curr Opin Pulm Med*. 2001; 7(6):404-406.

10. Fischer Y, Gosepath J, Amedee RG, et al. Radiofrequency volumetric tissue reduction (RFVTR) of inferior turbinate: A new method in the treatment of chronic nasal obstruction. Am J Rhinol. 2000; 14(6):355-360.
11. Rhee CS, Kim DY, Won TB, et al. Changes of nasal function after temperature-controlled radiofrequency tissue volume reduction for the turbinate. Laryngoscope. 2001; 111(1):153-158.
12. Utley DS, Goode RL, Hakim I. Radiofrequency energy tissue ablation for the treatment of nasal obstruction secondary to turbinate hypertrophy. Laryngoscope. 1999; 109(5):683-686.

اختزال المحارة السفلية للأنف بواسطة جهاز الترددات الراديوية

د. شامل عبود هلال

الملخص:

يعاني الكثير من مرضانا من تداعيات التضخم المزمن للمحارة السفلية الموجودة داخل التجويف الأنفي غير المتزامنة مع أعراض حساسية المجاري التنفسية العليا مما استدعى البحث عن أساليب عديدة لعلاجها وكانت إحدى هذه الطرق هو استخدام الترددات الراديوية لإزالة ذلك التضخم والتي اكتشفت وطورت أجهزتها خلال العقدين المنصرمين. حيث قمنا هنا بدراسة تأملية لتبيان فوائد ومساوئ استعمال هذه الطريقة في المعالجة. أجريت هذه الدراسة المنظورة للفترة من ٣ تموز ٢٠٠٩ لغاية ٤ أيلول ٢٠١٠ على ٣٧ مريض حيث تم إجراء اختزال المحارة السفلية بجهاز الترددات الراديوية تحت التخدير الموضعي وتمت متابعتهم حول مدى استجابتهم. لوحظ فعالية استخدام الترددات الراديوية وخلوه تقريبا من أي أعراض جانبية إضافة إلى سهوله استخدامه كبديل للعمليات التقليدية تحت التخدير العام.