

Cutaneous Manifestations in COVID-19 Patients Admitted to Al-Hussein Teaching Hospital in Dhi-Qar Province

**Dr.Dhulfiqar A. Kadhim,
Prof. Hadaf A. AL-Junaiyeh**

Abstract

Background: the cutaneous manifestations of COVID-19 are increasingly reported and they are important clues for early detection of SARS-CoV-2 infection.

Objective: To describe the different morphologies of skin and/or mucosal lesions associated with confirmed COVID-19 adult patients who have been admitted to the main quarantine hospital in Dhi-Qar province.

Patients and methods: All confirmed COVID-19 patients were examined for mucosal and/or cutaneous lesion, and those who had such manifestations were evaluated and subjected to a detailed history, a complete physical examination and photography for documentation. The patients were classified into five groups according to lesions' morphology; maculopapular, urticarial, pustular and papulovesicular, vasculitic and miscellaneous groups.

Results: Out of 3554 confirmed COVID-19 patients only 157 showed mucocutaneous manifestations, of them 116 patients were excluded for many reasons as cutaneous adverse drug reactions (CADR), other infections ...etc. The remaining 41 patients who represent (1.15%) were included and classified into; maculopapular (29.26%), urticarial (24.39%), pustular and papulovesicular (17.07%), vasculitic (14.63%) and miscellaneous (14.63%).

Conclusions: This study has shown that there are many cutaneous manifestations in COVID-19 disease that may differ from one country to another, while some are constant around the globe, so it is important for any doctor, not just the dermatologists, to recognize and bear these presentations in mind during this pandemic for early detection, better treatment and prevention of SARS-CoV-2 infection, hopefully that one day this pandemic is over by the collaboration of all of us.

Keywords: COVID-19, novel coronavirus, SARS-CoV-2.

Introduction

It is postulated that the pandemic of SARS-CoV-2 started in a seafood market in Wuhan at the 12th of December 2019 [1]. At the beginning, several cases were presented with atypical pneumonia, but the presentation had evolved to include many extra pulmonary manifestations as gastrointestinal tract, heart, kidneys, skin and mucous membranesetc[2].

The cutaneous manifestations reported in United States of America, Thailand and deferent western countries as Italy, France and Spain were mainly maculopapular, urticarial, pseudo-chilblain, livedoid and papulovesicular rashes [3].

In this study, a morphological discretion and classification of COVID-19 cutaneous manifestations have been proposed to help clinicians especially in asymptomatic or paucisymptomatic patients as it may contribute to earlier and better diagnosis and management of such patients.

Patients and methods

This is a cross-sectional study that was conducted in AL-Hussein Teaching Hospital (the main quarantine hospital dedicated to treat COVID-19 adult patients in Al-Nasiriyah City), Dhi-Qar, Iraq, during the period from (1st of Jun 2020) to (15th of September 2020).

All admitted confirmed COVID-19 patients were examined for the presence of cutaneous and/or mucosal lesion, those who did were evaluated and subjected to a detailed history, a complete physical examination and photography for documentation. Any patient who had a PCR negative, a known dermatological disease that was not altered during the course of infection, a presentation of a well-known cutaneous adverse drug reaction (CADR) with typical drug history, Any dermatosis caused by a known infectious agent as herpes simplex, candidiasis, scabies ...etc. or prolonged immobility and comorbidities as decubitus ulcer were excluded. The Ethical approval was gained from the Scientific Committee of the Scientific Council of Dermatology and Venereology, Iraqi Board for Medical Specializations and a verbal consent was obtained from each patient or their relatives, before

enrolling them in this study. The collected data were tabulated on (Microsoft Excel 2010) and assessed by percentages. The means, ranges, standard deviations and P-values were calculated by (IBM SPSS Statistics 23).The patients were classified into five groups according to lesions' morphology; maculopapular, urticarial, pustular and papulovesicular, vasculitic and miscellaneous groups.

Results

A total of 157 COVID-19 patients with mucocutaneous manifestations were evaluated (the total number of COVID-19 confirmed admitted patients during the same period was 3554) in Al-Hussein Teaching Hospital, of them 116 were excluded (3.26% of the total number) because their lesions were not the direct result of SARS-CoV-2 infection or complications (Table 1).

Table 1 The numbers and percentages of excluded patients.

Skin lesion	Number of patients	Percentage form the total 116 excluded patients	Percentage form the total 3554 admitted patients
Candidiasis	5	4.13	0.14
Recurrent herpes simplex	9	7.75	0.25
Herpes zoster	2	1.72	0.05
Scabies	1	0.86	0.02
Decubitus ulcer	8	6.89	0.22
Chronic dermatosis	7	6.03	0.19
Acneiform eruption	9	7.75	0.25
urticaria	12	10.34	0.33
ecchymosis	63	54.31	1.77
Total	116	100%	3.26%

In the remaining 41 patients, who represent 1.15% of the total number of COVID-19 patients during the study period; the age range was 18-72 years and the majority of patients were between 20-39 years with male to female ratio was 1.27:1, the COVID-

19 severity according to the National Health Commission of China severity classification of COVID-19[4] was; 17.07% mild, 51.21% moderate, 26.82% severe and 4.87% critical. The patients were classified clinically into 5 groups;

maculopapular, urticarial, pustular and papulovesicular, vasculitic and miscellaneous (Table 2).

Table 2 The characteristics of patients enrolled in the study. P value less than 0.05 is statistically significant.

characteristics	maculopapular	urticarial	pustular and papulovesicular	vasculitic	miscellaneous	total	P value
number of patients(percentage from the 41 patients)	12(29.26)	10(24.39)	7(17.07)	6(14.63)	6(14.63)	41	
Age, mean (SD) in years	38.16(14)	31.6(9.47)	45.85(21.09)	38.83(16.14)	42.5(18.11)		0.363
gender(percentage from total patients in each category)							0.833
male	7(58.33)	6(60)	2(28.57)	4(66.66)	4(66.66)	23	
female	5(41.66)	4(40)	5(71.42)	2(33.33)	2(33.33)	18	
mean duration from the onset of COVID-19 symptoms(SD) in days	5.41(3.39)	6(4.32)	10.42(4.89)	8.5(2.81)	17.83(10.81)		<0.001
COVID-19 severity(percentage from the total patients in each category)							0.031
mild	2(16.66)	3(30)	1(14.28)	0	1(16.66)	7	
moderate	7(58.33)	7(70)	1(14.28)	5(83.33)	1(16.66)	21	
severe	3(25)	0	5(71.42)	1(16.66)	2(33.33)	11	
critical	0	0	0	0	2(33.33)	2	

1- Maculopapular skin eruption:

This represents the most common pattern (Figure 1), which was seen in 12 patients (29.26%), it presents as erythematous macules (sometimes coalescing into patches) and papules, distributed mainly on the trunk, the extremities (specially the proximal areas) were also affected, sparing the palms, soles and mucous membranes. There were no scales and no associated lymphadenopathy. Mild itching was seen in 58.33% of patients. Generally, this type occurs more in mild to moderate cases of COVID-19 with a younger age group and earlier in the course of disease with an average of 5.41 days.

2- Urticated lesions:

This represents the second most common pattern (Figure 2).It was seen in 10 patients (24.39%). All the patients had transient wheals except for one patient who had dermatographism (Figure 3) without obvious wheals unless provoked. The itching ranged from mild to severe intractable and was the presenting symptom of SARS-CoV-2 infection along with high grade fever in two patients. Interestingly; neither palms nor soles were affected and no angioedema was observed.

3- Pustular and papulovesicular eruption:

Seven patients (17.07%) were seen having pustular and papulovesicular eruption, however; major differences were seen among those patients which made us categorize them into two subgroups:

Group A: in three patients the pustules erupted late in the disease course (mean 15 days) affecting the whole mouth with no other cutaneous or mucosal involvement, they were flaccid pustules with burning sensation which was severe enough to interfere with oral feeding. All the three patients were elderly females with mean age of 66.33 years recovering from severe COVID-19 (Figure 4).

Group B: the four patients who constituted this subgroup were younger (mean age is 30.5 years) and had a relatively earlier onset (mean duration is 7 days), they had an eruption of papules, vesicles and few pustules of rapid onset (but overall the lesions appeared monomorphic in each patient) spreading to involve the skin without mucosal involvement, except for one patient who had both cutaneous and mucosal involvement. The lesions were tense, some of them with a fluid level, the rash was mildly pruritic or asymptomatic with fever being a prominent feature. The main site of involvement was the trunk with scattered lesions on the face and extremities. Of note, three of the patients had a childhood history of chicken pox and one of them didn't recall. The severity of COVID-19 ranged from mild to severe (Figure 5).

4- Vasculitic lesions:

The differences in the presentation of the six patients of this group (14.63%) necessitated the division into two forms:

Group A: palpable purpura was on the lower extremities of three middle aged (mean 52 years) male patients with moderate to severe SARS-CoV-2 infection, the rash was asymptomatic, erupted within a mean of 10 days of the onset in the form of dusky erythematous papules and plaques of the legs in a bilateral symmetrical distribution (Figure 6).

Group B: in this group, acral edema and patches of dusky erythema (Kawasaki-like) were seen in two females and one male of a younger age (mean 25.66 years) with moderate COVID-19, all of them had high grade fever with no mucous membrane

involvement or lymphadenopathy. The rash started within a mean of 7 days of the onset (Figure 7).

5- Miscellaneous cases:

This group is dedicated for rare manifestations that were seen in one or two patients only:

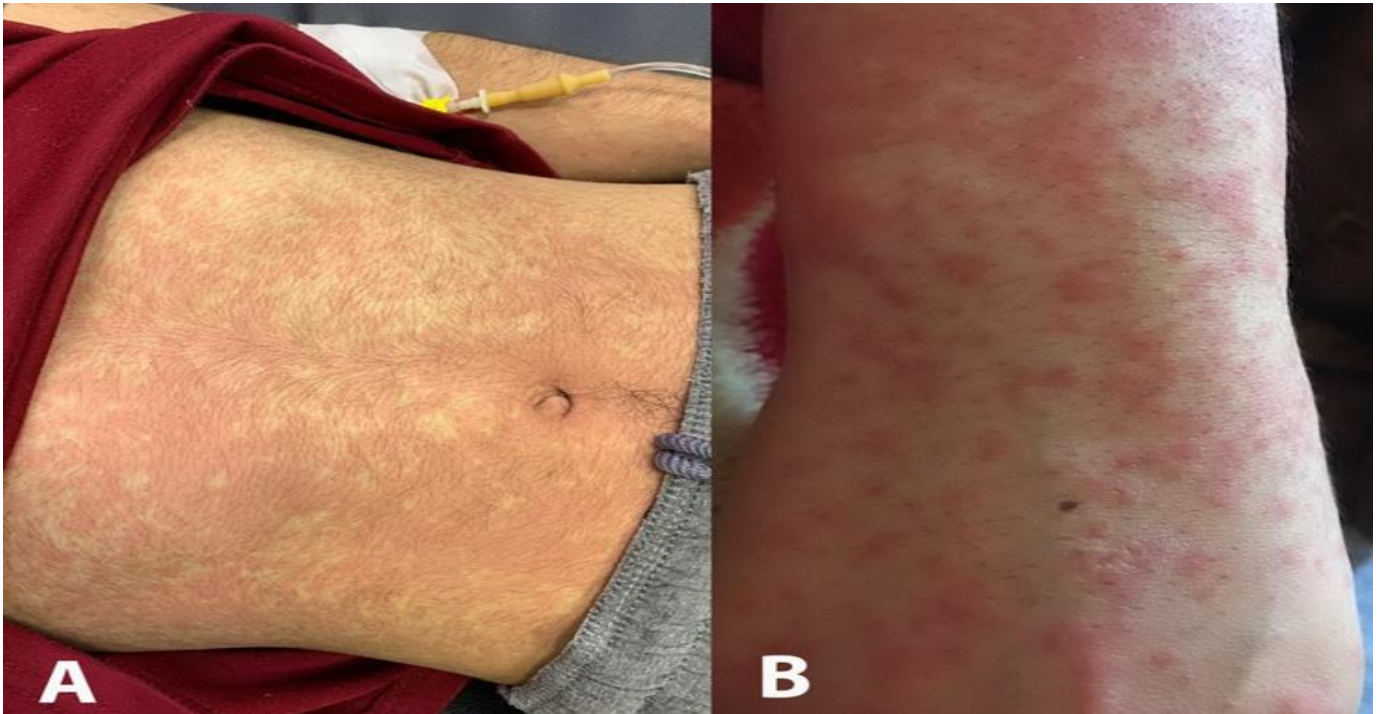
A-Two middle aged patients; a male and a female, who had a severe COVID-19 disease, developed a painful oral aphthosis after about 30 days from the onset without a prior history of the same condition (Figure 8).

B-Two male patients with critical COVID-19 infection developed a sudden painful unilateral limb ischemia; the first one was 27 years old, a diagnosis of arterial embolism was established by CT-angiography followed by an emergency embolectomy. The patient's condition improved temporarily, but he died from massive pulmonary embolism 10 days later (Figure 9). The second patient was 57 years old with the same presentation; he ended up with gangrene and amputation.

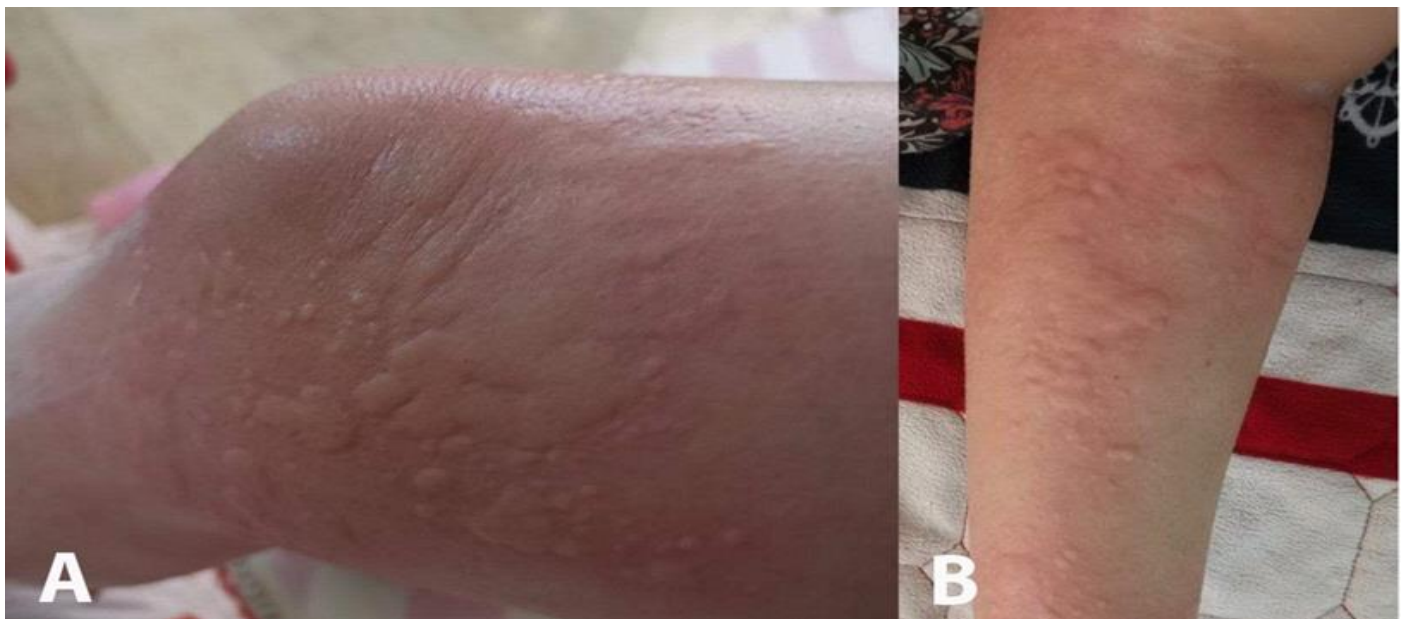C-A forty years old lady presented with ecchymosis, petechiae and epistaxis 11 days from the onset of a persistent low grade fever, the complete blood count showed anemia with elevated reticulocyte count, thrombocytopenia and normal leukocytes count, the blood picture showed normal cells morphology (Figure 10).

D-A peculiar granuloma annulare-like lesions erupted bilaterally on the elbows of 31 years male patient with mild COVID-19 disease after 5 days from the onset. The eruption was very itchy and lasted for two weeks; he had no previous history of a similar condition (Figure 11).

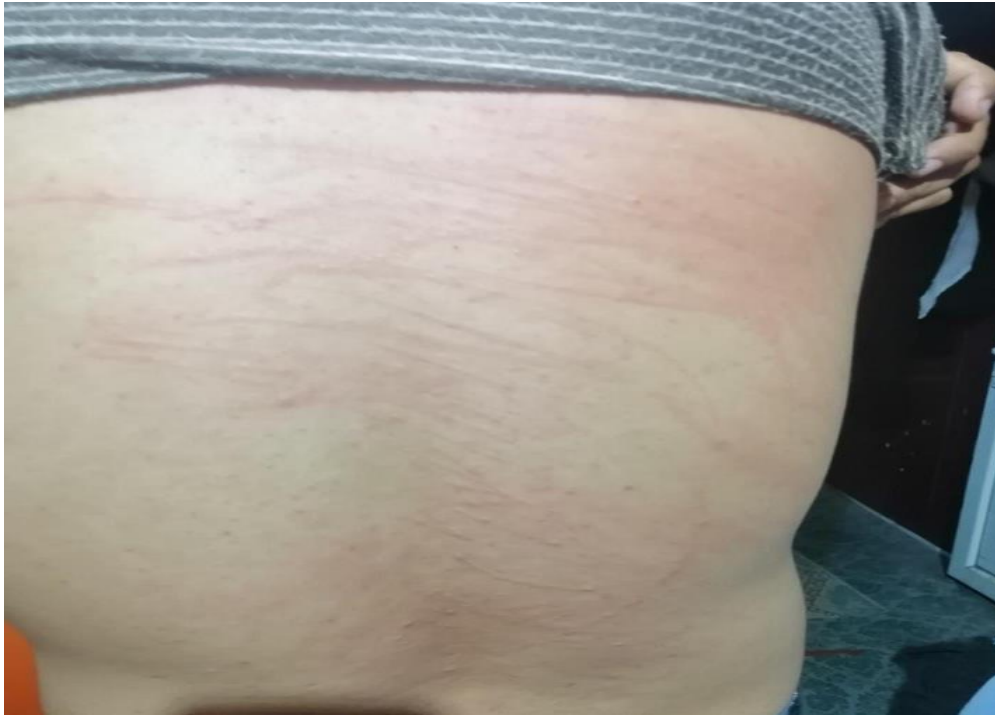The statistical analysis of data showed a significant association between the pattern of skin lesion morphology and the COVID-19 severity on one hand and the latency period between the onset of COVID-19 first symptoms and the appearance of cutaneous and/or mucosal lesions on the other hand as noted from the P-values; of 0.031 and <0.001 respectively.



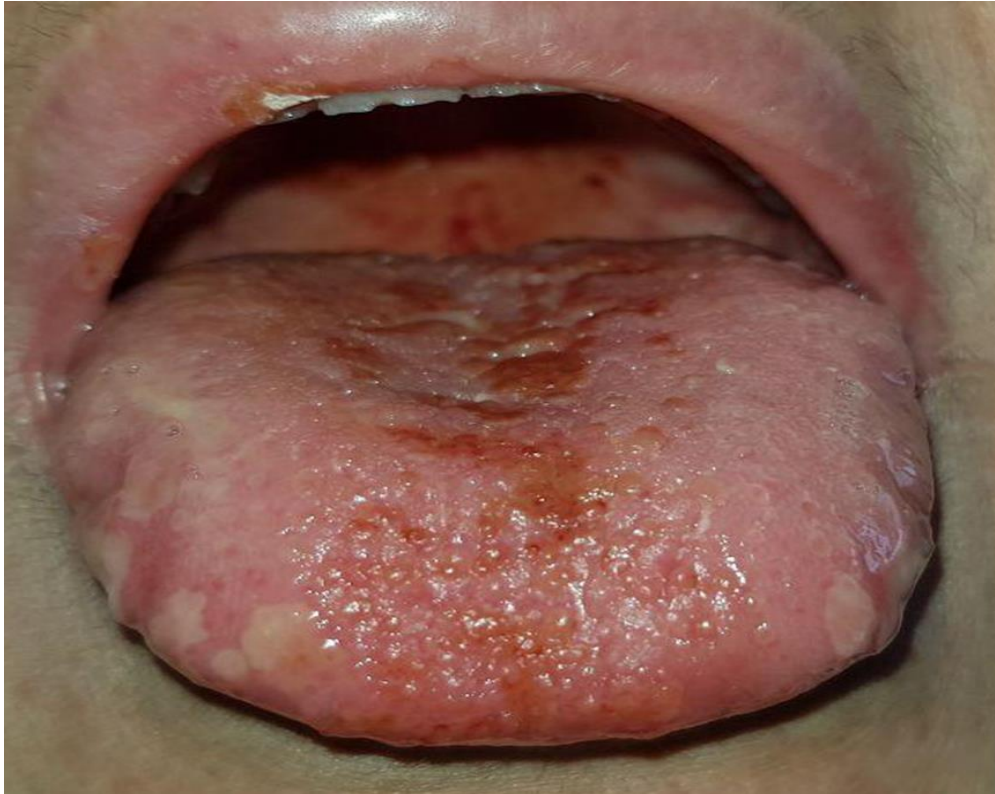(Figure 1) Maculopapular skin eruption in COVID-19 patient. (A) the abdomen and (B) the dorsum of the hand of the same patient.



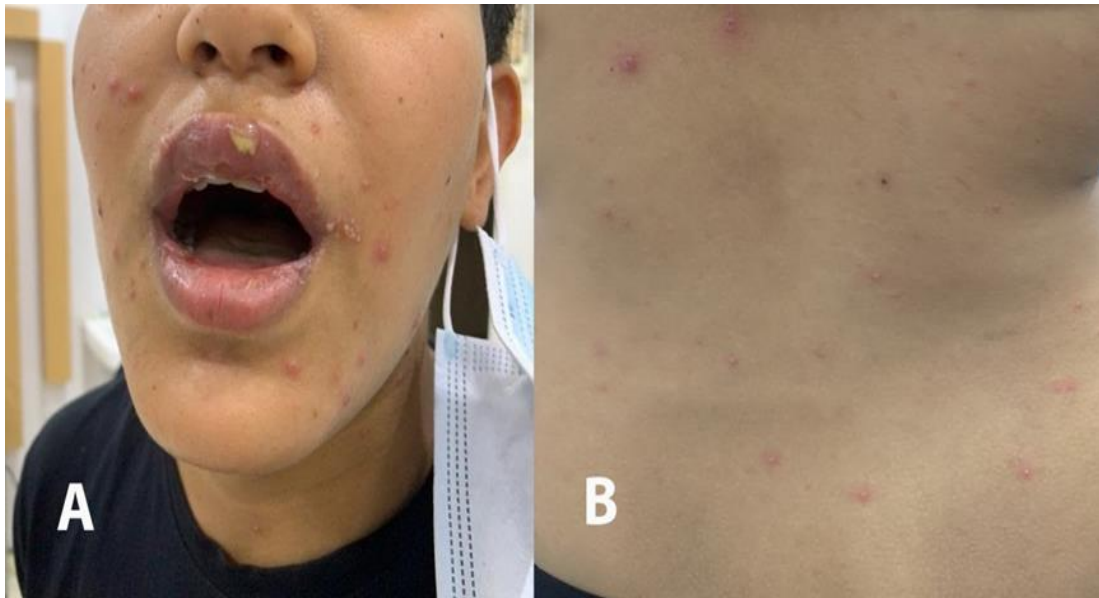(Figure 2) Wheals on the leg (A) and the arm (B) of a young COVID-19 patient.



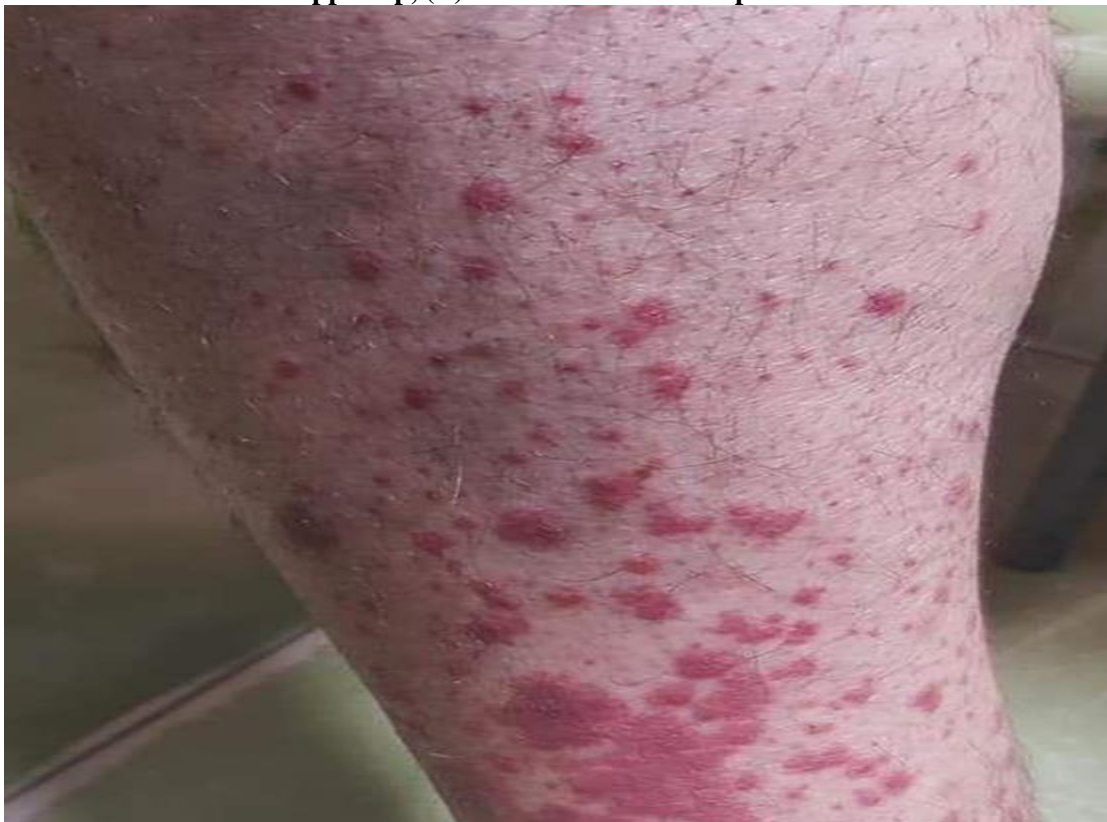(Figure 3) Dermographism in COVID-19 patient.



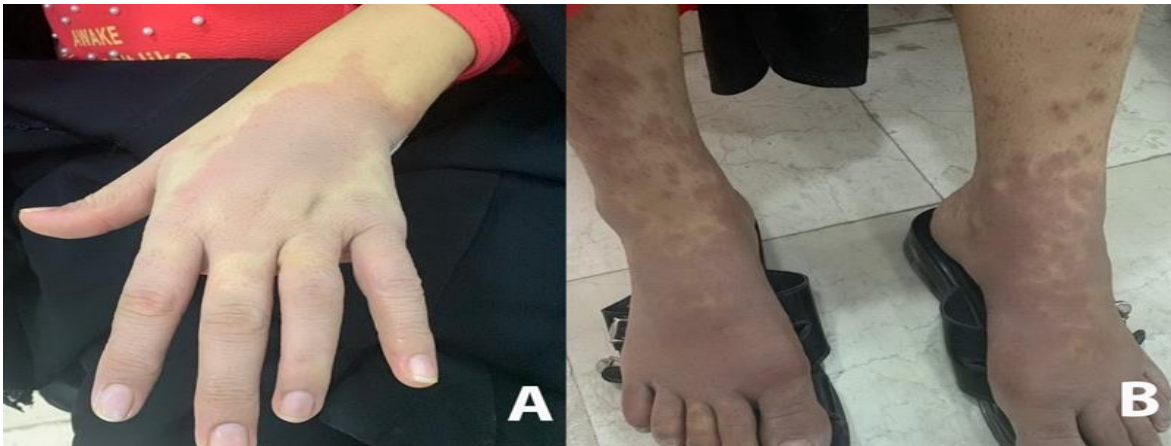(Figure 4) Pustules affecting the mouth which are evident on the side of the tongue.



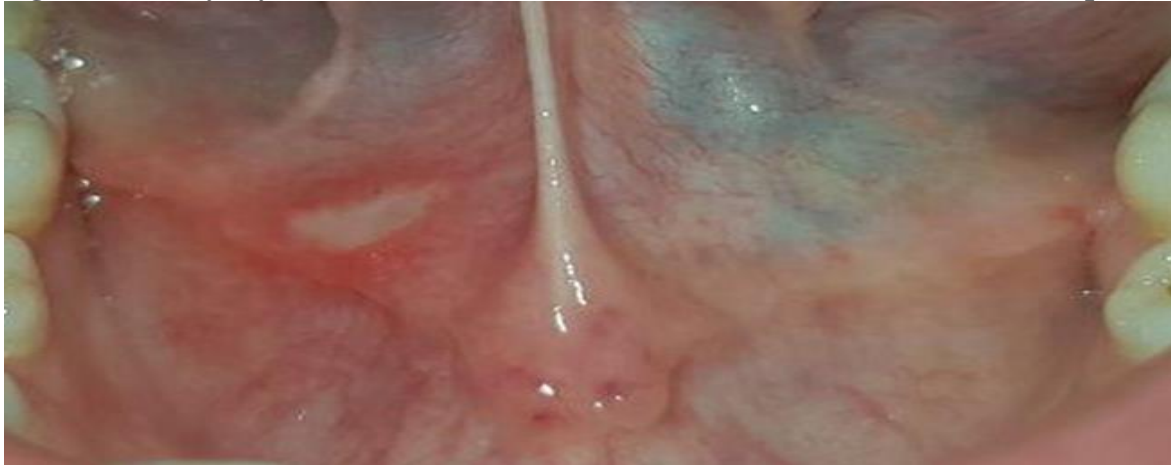(Figure 5) Papulovesicles and pustules (A) affecting the face with evident fluid level on the upper lip, (B) the back of the same patient.



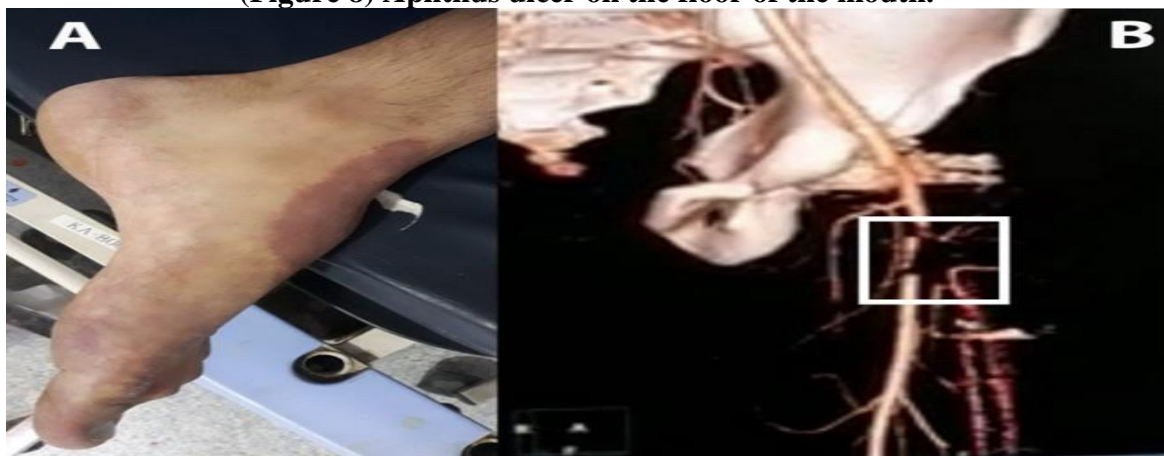(Figure 6) Palpable purpura affecting the lower leg.



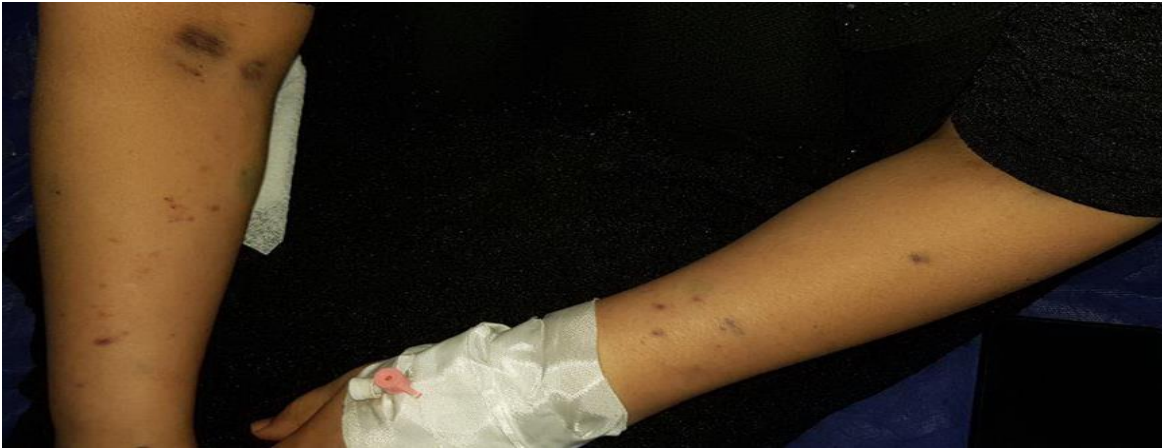(Figure 7) Dusky erythema and edema (A) the hand and (B) the feet of the same patient.



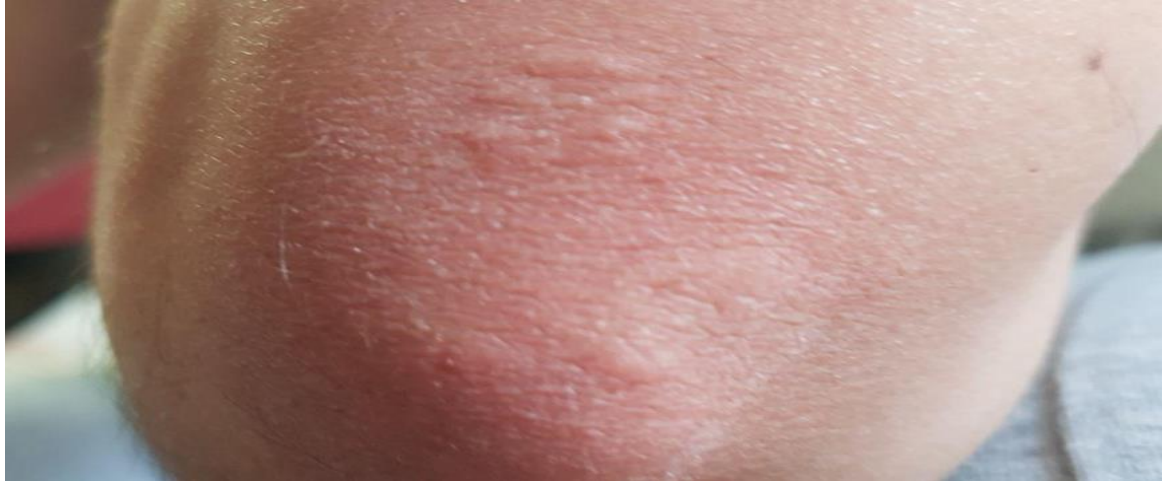(Figure 8) Aphthous ulcer on the floor of the mouth.



(Figure 9) Unilateral acute limb ischemia: (A) clinical and (B) CT-angiographic pictures with the rectangle highlighting the site of arterial obstruction.



(Figure 10) Petechiae and ecchymosis in COVID-19 patient who developed thrombocytopenia.



(Figure 11) Granuloma annulare-like presentation in a COVID-19 patient.

To date, we are living at a time of a new virus pandemic that we don't know much about its evolving general manifestations which differ from one country to another including its mucocutaneous ones. This study describes the different morphologies of cutaneous and/or mucosal lesions associated with confirmed COVID-19 adult patients who had been admitted to the quarantine hospital in Al- Nasiriyah city, south of Iraq. Four main clinical patterns were observed; maculopapular, urticarial, pustular and papulovesicular and vasculitic lesions, in addition to a fifth group of miscellaneous cases of one or two patients who manifested distinct cutaneous lesions. Some of these patterns have been reported in previous studies [5] with larger sample size, but in contrast to this study they included the suspected and close contact cases in addition to the confirmed cases of COVID-19, this might explain

their larger sample size compared to our smaller one; where only PCR-proved patients were included, but also might not give the real impression of the true mucocutaneous manifestations that are directly related to SARS-CoV-2 infection as there is till now no single test to correlate those lesions with SARS-CoV-2 infection other than the exclusion of other possibilities.

The maculopapular pattern was the most common pattern (29.26%); this is in accordance with other studies from Spain [6], Italy [7] and a larger meta-analysis study [5]. It was observed mostly in young adults with mild to moderate COVID-19, with some times high grade fever. The distribution was mainly in the trunk with little involvement of the extremities, this is similar to reports from Italy [7], France [8] and USA [9], only one study [10]

reported one patient with only face and acral distribution of the rash.

The presentation of acute urticaria in COVID-19 patients was noted early in the disease course and mostly in young adults with mild to moderate infection without associated angioedema; similar results have been reported in the literatures [6,11]. The itching was severe and poorly responding to the usual doses of antihistamines, but the inclusion of systemic steroids in the COVID-19 management protocol; contributed to a better outcome of urticaria. Drugs, especially cephalosporin antibiotics, might be the cause of acute urticaria, this led to the exclusion of twelve patients who have been taking these medications and the onset of urticaria was immediately after the initiation of the treatment, this might underestimate the actual frequency of such eruption in those patients. Acute urticaria was the initial presentation of SARS-CoV-2 infection in one study [12], in another study; urticarial rashes were asymptomatic [13]. No similar presentation had been observed. But a case of dermatographism in a young patient was reported and this has not been reported previously in the literature.

The papulovesicular eruption was mainly seen in young patients mostly on the trunk, this is similar to other reports [6,7,14]. However, three severely affected COVID-19 patients with a pustular eruption limited only to the oral mucosa had been reported in this study, which appeared somewhat late (about two weeks) in the disease course; this finding has not been reported previously.

Also there were three cases with manifestations of the cutaneous element of Kawasaki disease in whom acral dusky erythematous edematous patches and plaques without mucosal involvement or lymphadenopathy were observed. They were young (20-26 years) with moderate COVID-19 severity. No similar reports were found in the literature; nonetheless two studies [15,16] had reported similar findings in pediatric patients.

Three patients presented with vasculitis on the lower limbs, they were middle aged, moderately affected and the rash erupted late in the disease course. The clinical presentations of vasculitis reported in the literature were mainly urticarial

vasculitis, erythema multiforme and Kawasaki disease [17,18].

Only two patients with oral aphthosis were seen, they were middle aged, the lesions erupted late in the course of disease and the aphthae were 1-3 in number. This is in contrast to the literature [19] where the patients were young, developed the ulceration early in the course of the disease with a number of 1-7. The lower frequency of such lesions might be explained by the early discharge of patients due to the shortage of hospital capacity.

Two patients with acute limb ischemia were recorded; one died from massive pulmonary embolism 10 days after the leg ischemic event, similar report came from Wuhan [20].

A case with petechiae and low platelet count has been observed similar to reports from Thailand [21].

A 31- year- old man developed a granuloma annulare-like intensely itchy eruption on the elbows with no history of such lesions or any drugs taken before the onset. This was attributed to SARS-CoV-2 infection as a potential cause; however this was not reported previously.

Reports of Pernio-like lesions from France [22], Spain [6] and Italy [23] were seen , but no such findings had been observed, this might be explained by the hot weather during the study period (1st of June - 15th of September 2020), however two such cases were reported from Kuwait [24] early in April 2020 .

There are many theoretical explanations for the cutaneous lesions associated with COVID-19 as the direct viral infection of basal keratinocytes (due to the expression of ACE2 receptors in those cells of keratinized and non-keratinized epithelium [25]) in papulovesicular and pustular eruptions, the inflammatory mediated skin injury in maculopapular, urticarial lesions and vasculitic rashes, coagulopathies in ischemic manifestations [26] , but the real pathogenesis is still in doubt and needs further investigations as smears or skin biopsy to elaborate the true mechanisms behind these lesions.

The real incidence of mucocutaneous manifestation of COVID-19 might be much more than reported due to the fact that lately only severe to critical cases were admitted to hospitals and most patients

with mild to moderate disease were managed at home. In conclusions this study has shown that there are many cutaneous manifestations of COVID-19 patients that could be different from one country to another, while some of which are still the most frequent around the globe, so it is important for any doctor, not just the dermatologists, to recognize and bear these presentation in mind during this pandemic for early detection of COVID-19 patients (if they presented with cutaneous and/or mucosal lesions as the sole manifestation of the disease) for

home. better treatment and prevention, hopefully that one day this pandemic is over by the collaboration of all of us.

Further studies on a larger scale are required to assess the actual incidence of COVID-19 mucocutaneous manifestations, and the possible mechanisms by which SARS-CoV-2 causes those skin and/or mucosal lesions should be clearly elaborated.

References

- 1- Zhu N, Zhang D, Wang W, Li X, Yang B, Song J, et al. A novel coronavirus from patients with pneumonia in China, 2019. *N Engl J Med.* 2020;382(8):727–33.
- 2- Gupta A, Madhavan MV, Sehgal K, Nair N, Mahajan S, Sehrawat TS, et al. Extrapulmonary manifestations of COVID-19. *Nat Med.* 2020 Jul;26(7):1017-1032.
- 3- Elmas ÖF, Demirbaş A, Özyurt K, Atasoy M, Türsen Ü. Cutaneous manifestations of COVID-19: A review of the published literature. *Dermatologic therapy.* 2020 Jul;33(4):e13696.
- 4- Leng Z, Zhu R, Hou W, Feng Y, Yang Y, Han Q, et al. Transplantation of ACE2-mesenchymal stem cells improves the outcome of patients with COVID-19 pneumonia. *Aging and disease.* 2020;11(2):216.
- 5- Rahimi H, Tehranchinia Z. A comprehensive review of cutaneous manifestations associated with COVID-19. *BioMed research international.* 2020 Jul 5;2020.
- 6- Galván Casas C, Catala AC, Carretero Hernández G, et al. Classification of the cutaneous manifestations of COVID-19: a rapid prospective nationwide consensus study in Spain with 375 cases. *British Journal of Dermatology.* 2020;183(1):71-7.
- 7- Recalcati S. Cutaneous manifestations in COVID-19: a first perspective. *Journal of the European Academy of Dermatology and Venereology.* 2020 Mar 26.
- 8- Mahé A, Birckel E, Krieger S, Merklen C, Bottlaender L. A distinctive skin rash associated with Coronavirus Disease 2019?. *Journal of the European Academy of Dermatology and Venereology.* 2020 Apr 15; 34:246–247.
- 9- Najarian DJ. Morbilliform exanthem associated with COVID-19. *JAAD Case Reports.* 2020 Jun;6(6):493.
- 10- Henry D, Ackerman M, Sancelme E, Finon A, Esteve E. Urticarial eruption in COVID-19 infection. *Journal of the European Academy of Dermatology and Venereology.* 2020 Apr 15;34:244–5.
- 11- Morey-Olivé M, Espiau M, Mercadal-Hally M, Lera-Carballo E, García-Patos V, et al. Skin manifestations in the context of the current outbreak of coronavirus disease 2019. In *Anales De Pediatría .*2020;92:374-5.
- 12- van Damme C, Berlingin E, Saussez S, Accaputo O. Acute urticaria with pyrexia as the first manifestations of a COVID-19 infection. *Journal of the European Academy of Dermatology and Venereology.* 2020;34(7):e300-e301.
- 13- Paolino G, Canti V, Santo Raffaele Mercuri PR, Candiani M, Pasi F. Diffuse cutaneous manifestation in a new mother with COVID-19 (SARS-Cov-2). *International Journal of Dermatology.* 2020;59(7): 874-5.
- 14- Tamaro AN, Adebajo GA, Parisella FR, Pezzuto A, Rello J, et al. Cutaneous manifestations in COVID-19: the experiences of Barcelona and Rome. *Journal of the European Academy of Dermatology and Venereology.* 2020 Apr 24.
- 15- Pouletty M, Borocco C, Ouldali N, Caseris M, Basmaci R, Lachaume N, et al. Paediatric multisystem inflammatory syndrome temporally associated with SARS-CoV-2 mimicking Kawasaki disease (Kawa-COVID-19): a multicentre cohort. *Annals of the Rheumatic Diseases.* 2020 Jun 11;79: 999–1006.
- 16- Jones VG, Mills M, Suarez D, Hogan CA, Yeh D, Segal JB, et al. COVID-19 and Kawasaki disease: novel virus and novel case. *Hospital Pediatrics.* 2020 Jun 1;10(6):537-40.
- 17- Almashat SA. Vasculitis in COVID-19: a literature review. *J vasc.* 2020 May;6(1):1-5.
- 18- Recalcati S, Barbagallo T, Frasin LA, Prestinari F, Cogliardi A, Provero MC, et al. Acral cutaneous lesions in the time of COVID-19. *Journal of the European Academy of Dermatology and Venereology.* 2020 Apr 24.
- 19- Dominguez-Santas M, Diaz-Guimaraens B, Fernandez-Nieto D, et al. Minor aphthae associated with SARS-CoV-2 infection. *International Journal of Dermatology.* 2020 ;59(8):1022-1023.
- 20- Zhang Y, Cao W, Xiao M, Li YJ, Yang Y, Zhao J, et al. Clinical and coagulation characteristics in 7 patients with critical COVID-2019 pneumonia and acro-ischemia. 2020;41(4):302-7.
- 21- Joob B, Wiwanitkit V. COVID-19 can present with a rash and be mistaken for Dengue. *Journal of the American Academy of Dermatology.* 2020;82(5):e177.

- 22- Hedou M, Carsuzaa F, Chary E, Hainaut E, Cazenave-Roblot F, Masson Regnault M. Comment on "Cutaneous manifestations in COVID-19: a first perspective" by Recalcati S. Journal of the European Academy of Dermatology and Venereology. 2020 Apr 21.
- 23- Tosti G, Barisani A, Queirolo P, Pennacchioli E, Villa L, Lodeserto AM, et al. Skin signs resembling vascular acrosyndromes during the COVID-19 outbreak in Italy. Clinical and Experimental Dermatology. 2020 May 2.
- 24- Alramthan A, Aldaraji W. Two cases of COVID-19 presenting with a clinical picture resembling chilblains: first report from the Middle East. Clinical and experimental dermatology. 2020 Apr 17.
- 25- Hamming I, Timens W, Bulthuis ML, Lely AT, Navis GV, van Goor H. Tissue distribution of ACE2 protein, the functional receptor for SARS coronavirus. A first step in understanding SARS pathogenesis. The Journal of Pathology: A Journal of the Pathological Society of Great Britain and Ireland. 2004;203(2):631-7.
- 26- Criado PR, Abdalla BM, de Assis IC, de Graaff Mello CV, Caputo GC, Vieira IC. Are the cutaneous manifestations during or due to SARS-CoV-2 infection/COVID-19 frequent or not? Revision of possible pathophysiologic mechanisms. Inflammation Research. 2020 Jun 5:1.

المظاهر الجلدية لدى مرضى كوفيد-19 الراقدين في مستشفى الحسين التعليمي بمحافظة ذي قار

د. نوالفقار علي كاظم

د. هدف عبد الامير جنيح

الخلاصة

اساس الدراسة: منذ بداية جائحة فايروس سارس-كوف-2 في كانون الأول 2019 ، تطورت الأعراض السريرية لـ كوفيد-19 لإظهار العديد من المظاهر خارج الرئة بما في ذلك الجلد والأغشية المخاطية. على الرغم من عدم الإبلاغ عنها بشكل متكرر ، فإن المظاهر الجلدية المخاطية للمرض مهملة للأطباء خاصة في المرضى الذين يعانون من ندرة الأعراض لأنها قد تساهم في تشخيص المرض ومعالجته بشكل أسرع وأفضل.

الهدف من الدراسة: وصف الأشكال المختلفة للآفات الجلدية أو المخاطية المرتبطة بمرضى كوفيد-19 البالغين المثبتة إصابتهم بواسطة فحص تفاعل البلمرة المتسلسل والذين تم إدخالهم إلى مستشفى الحجر الصحي الرئيسي في محافظة ذي قار. المرضى وطرائق عمل البحث: هذه الدراسة هي دراسية مقطعية ، أجريت في مستشفى الحسين التعليمي (مستشفى الحجر الصحي الرئيسي المخصص لعلاج مرضى كوفيد-19 البالغين في مدينة الناصرية)/ ذي قار/ العراق ، خلال الفترة من الأول من شهر حزيران 2020 إلى الخامس عشر من شهر أيلول 2020 . تم تقييم جميع مرضى كوفيد-19 المصابين بأفة مخاطية أو جلدية و استحصال تاريخ مرضي مفصل و إخضاعهم الى فحص جسدي كامل مع تصوير الآفات بواسطة الكاميرا لغرض التوثيق. تم تصنيف المرضى إلى خمس مجموعات حسب العلامات المظهرية لتلك الآفات: مجموعات لطاخية حطاطية ، شرويه ، بثرية و حطاطيه حويصلية ، وعائية ومتنوعة.

النتائج: من بين 3554 مريضاً كوفيد-19 مؤكداً الاصابة أظهر 157 فقط مظاهر جلدية و مخاطية ، منهم 116 مريضاً تم استبعادهم لأسباب عديدة مثل التفاعلات الدوائية الجانبية والتهابات الأخرى ... إلخ. تم تضمين الواحد والأربعين مريض الباقين الذين يمثلون (1.15%) من اجمال المرضى المؤكدة اصابتهم وتصنيفهم إلى ؛ لطاخ ي حطاطي (29.26%) ، شري (24.39%) ، بثري و حويصلي حطاطي (17.07%) ، وعائي (14.63%) و متنوع (14.63%).

الاستنتاجات: أظهرت هذه الدراسة بأن هناك العديد من المظاهر الجلدية في مرض كوفيد-19 والتي يمكن أن تختلف من بلد إلى آخر ، في حين أن بعضها ثابت التكرار في جميع أنحاء العالم ، لذا من المهم أن يتعرف عليها أي طبيب ، وليس فقط أطباء الأمراض الجلدية، وكذلك من المهم الأخذ بهذه العروض في نظر الاعتبار خلال هذا الوباء من أجل الاكتشاف المبكر والعلاج الأفضل والوقاية من عدوى فايروس السارس-كوف-2، أملين في أن ينتهي هذا الوباء يوماً ما بتعاوننا جميعاً.