

# Osteomyelitis of Symphysis Pubis: Case Report

Haider Shaheed Mohammed, lecturer, College of medicine, University of Thiqar, e-mail: [Hayder.sh@utq.edu.iq](mailto:Hayder.sh@utq.edu.iq),

Hussein Ali Hamad, Consultant Surgeon, Al-Nassiriyah Teaching Hospital  
Rafid Remthan Hussein, Clinical Radiologist, DMRD, CABMs, Al-Hussein Teaching Hospital

## Abstract

Osteomyelitis of symphysis pubis is rare existence with ensuing deleterious sequela if not diagnosed swiftly and treated decently. Diverse reviews in publications about inflammatory, infective, and septic insult at this locus. As a matter of fact the diagnosis of this entity is oftentimes overlooked due to rareness, ambiguity, and resemblance with other simulating ailment thus impeding the diagnosis with accompanying ramifications incorporating abscess. We present a case of osteomyelitis of symphysis pubis in 23 years old male who misdiagnosed with durable deferral and displaying as an abscess that mandating invasive intervention highlighting that physician should have had lower threshold for maintaining suspicion of this infrequently encountered entity.

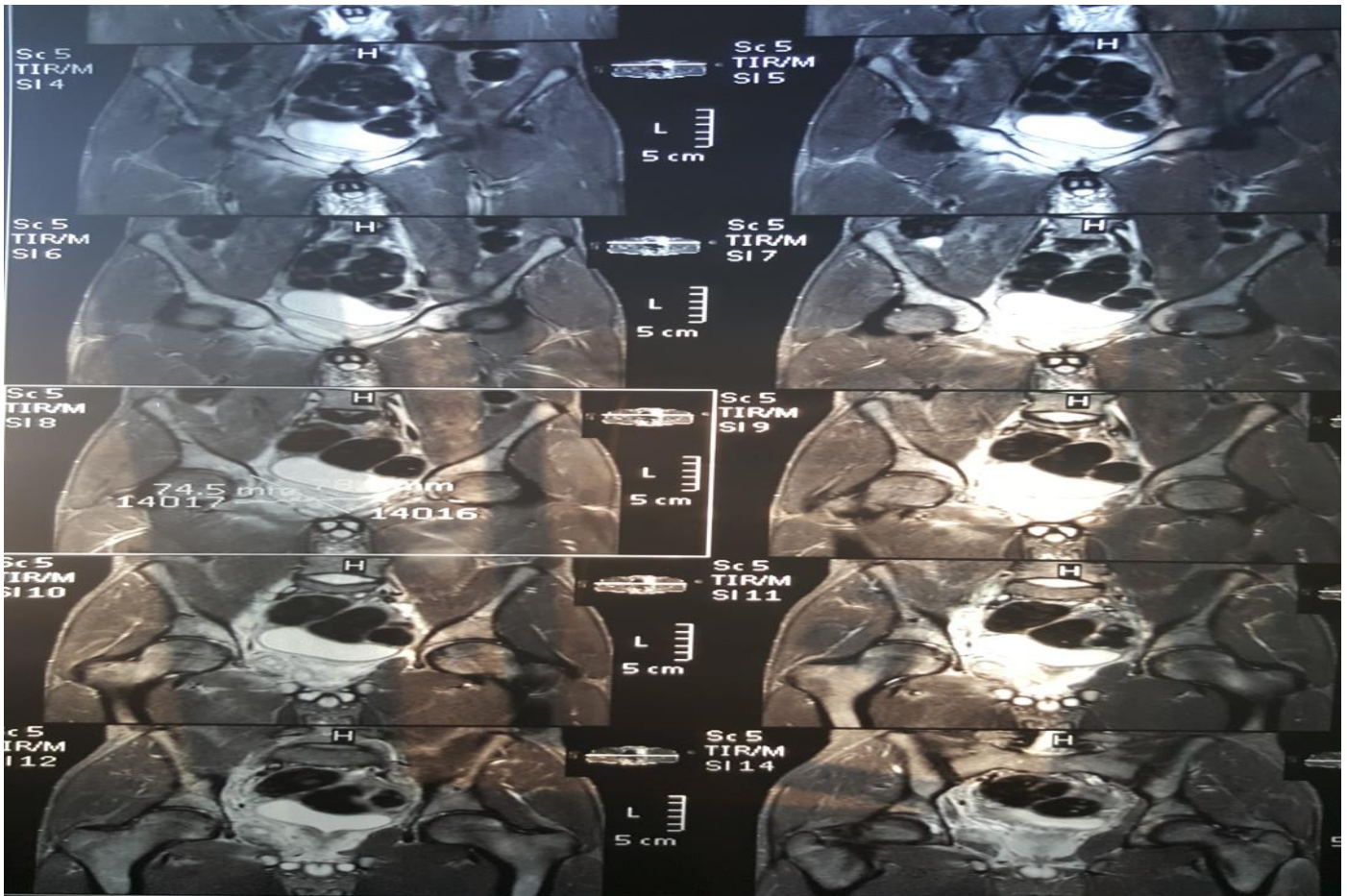
## Introduction:

osteomyelitis of pubis symphysis is an exceedingly sparse and grave type of osteomyelitis, athletics among other several vulnerable conditions have the potentiality for predisposition to this ailment[1]. The obscurity in presentation and the factuality that this illness can simulate a miscellany of almost identical clinical entities make the diagnosis is a difficult task both clinically and radiologically[2]. we introduce a case that seeks our medical services in our institution with postponed diagnosis and inconspicuous features mandating the essence of keeping alertness and high degree of clinical skepticism for this devastating entity.

## Patient and observation

A 23 years old male, well competent athletics complained of fever for one and half month with sweating, loss of appetite, fatigability, and pain at right inguinal area that is referred to hip joint with concomitant restriction in all ranges of movement, the symptoms appeared ten days after he exposed to trauma and fall while doing football game with resultant small wound discharging pus around ankle treated by paramedics by dressing and oral antibiotics. The only remarkable finding on clinical examination is exquisite local tenderness over symphysis pubis with

enlargement of inguinal lymph nodes, he was afebrile. The abdominal examination revealed tip of spleen palpable, normal genitalia examination as well as urinalysis. The white blood cells is 23480 per mm<sup>3</sup>. The erythrocyte sedimentation rate is 85 mm/h. the peripheral blood smear shows lymphocytosis with neutrophilia with left shift and reactive lymphocytes. The blood culture was negative. Ultrasonography shows abnormal echogenicity in lower adductor muscle, mild splenomegaly with inguinal lymph nodes enlargement. MRI of pelvis shows collection around superior ramus of right pubic bone with bone marrow edema (figure 1). The patient was instituted on vancomycin 0.5 g twice and surgical consultation was performed, the surgeon decide to drain the deep abscess with debridement and inguinal lymph node resection for biopsy which revealed reactive adenitis, the patient did well postoperatively with antibiotics continued for four months, before discharge the white blood cells decreased to 6200 cell per mm<sup>3</sup>, the Erythrocyte sedimentation rate decreased to 45mm with substantial clinical improvement in all spectrum of his systemic and local manifestations



figure(1): MRI of pelvis shows evidence of abscess surrounding superior ramus of right pubic bone with bone marrow edema.

## Discussion

The pubic symphysis is a midline joint that anchor both superior pubic rami[3]. Inflammatory insult and infective focus at this site is a notable complication of sport activities especially football players whose activities involved over adduction[4]. Osteomyelitis of pubic bone presents with pain at pubic, suprapubic, and

testicular areas with painful abduction and limping gait with difficulty of weight bearing[5].

Osteitis pubis is rare a sterile inflammatory condition that is highly mimic the rarer septic arthritis of symphysis pubis and need to be discerned from this condition[6]. Osteomyelitis of symphysis pubis is characterized by fever, pain, and positive blood culture, The etiological pathogen that is implicated in septic arthritis is *Staphylococcus aureus* [7]. The pathogenesis mainly involved edema secondary to repeated trauma with consequent seeding, translocation and colonization of bacteria at this site[1]. There is delay in diagnosis if radiological modalities other than MRI were used so MRI is the most sensitive investigation picking an early diagnosis[7]. In our case the prolonged delay in the diagnosis were caused by lack of maintaining thinking about the diagnosis despite the typical symptomatology of the condition, the delay in the diagnosis was complicated by abscess formation with consequent invasive approach. Prolonged antibiotics therapy with drainage of abscess is the ideal treatment of this condition[8]. Early vigilance and awareness to the diagnosis is essential in preventing the morbidity and requiring of invasive treatment.

## Conclusion

osteomyelitis of symphysis pubis is a rare and potentially catastrophic condition requiring early vigilance and high index of clinical suspicion, a combination of clinical, radiological, and microbiological with a microbiology-aided prolonged antibacterial therapy

## References

1. Justin Y,David C. Osteomyelitis pubis: A rare and Elusive Diagnosis. Western Journal of Emergency Medicine.2014 Nov;15(7):880-882.doi:10.5811/westjem.2014.8.13401.PMCID:PMC4251242.PMID:25493141.
2. Saad M A,Fan J,Bardia B,et al.Symphysis Pubis Osteomyelitis with Bilateral Adductor Muscles Abscess, case reports in orthopedics,vol.2014,Article ID 982171,3 pages,2014.<https://doi.org/10.1155/2014/982171>.
3. Leila K,Jonelle M,Petscavage,et al.Postpartum symphysis pubis diastasis. Radiology case Reports.2011;6(3):542.PMCID:PMC4900060.PMID:27307920.
4. Vipul,K.,&Donato,A.A.(2007).Spontaneous pubic osteomyelitis-a rare cause of groin pain. Journal of General Internal Medicine,22(Issue1),234-235.
5. Pauli S,Willemsen P,Declerck K,Chappel R,et al.Osteomyelitis pubis versus Osteitis Pubis: a case presentation and review of the literature. British Journal Of Sport Medicine, volume 36,Issue 1.
6. Patrick Gomella,and Patrick Mufarrij.Reviews In Urology.2017;19(3):165-163.doi:10.3909/riu0767.PMCID:PMC5737342.PMID:29302238.
7. Imane E,Fatema Z A,Samia M,et al.Septic arthritis of the pubic symphysis: a case report. The Pan African Medical Journal, volume 18,Article 149,17 Jun 2014/10.11604/pamj.2014.18.149.4421.
8. Stefano C,Fulvio B,Chiara B.Osteomyelitis of the pubic Symphysis caused by methicillin-resistant Staphylococcus aureus after vaginal delivery: a case report and literature review.BMC Infectious Diseases 19,952(2019).<https://doi.org/10.1186/s12879-019-4595-x>.

## التهاب العظم والنقي في ارتفاع العانة | تقرير حالة

حيدر شهيد محمد، كلية الطب جامعة | ذي قار العراق، [mail:Hayder.sh@utq.edu.iq](mailto:Hayder.sh@utq.edu.iq)  
حسين علي حمد، جراح استشاري، مستشفى الناصرية التعليمي  
رافد رمثان حسين، اخصائي الأشعة التشخيصي، مستشفى الحسين التعليمي  
الملخص

التهاب العظم والنقي الناتج عن ارتفاع العانة هو وجود نادر الحدوث مع عقابيل ضاره اذا لم يتم تشخيصها بسرعة وعلاجها بشكل لائق. مراجعات متنوعة في المنشورات حول الالهانات الالتهابية والمعدية والتفسيخية في هذا المكان. في واقع الامر غالبا ما يتم التغاضي عن تشخيص هذا الكيان بسبب الندرة والغموض والتشابه مع امراض محاكاة أخرى، مما يعيق التشخيص مع التداعيات المصاحبة التي تتضمن الخراج. نقدم حالة التهاب العظم والنقي لارتفاع العانة عند ذكر يبلغ من العمر 23 عاما والذي تم تشخيصه خطأ مع تأخير طويل الامد وتمت اعراضه كخراج بحاجة الى التدخل الجراحي مسلطا الضوء على ان الطبيب كان يجب ان يكون لديه عتبة اقل للحفاظ على الشك في هذا الكيان الذي نادرا ما يصادفه