

## **Intramasseter Venous Malformation With Phleboliths: A Case Report**

**Rabab Abass Hasan ( MBChB, FICMS Plastic-Reconstructive Surgery ) /**

**College of Medicine / Thi-Qar University**

### **Introduction**

Venous malformation is the most common vascular malformation, and is low flow type. About 40% of cases present in the area of head and neck. They are divided into superficial and deep types. Superficial type involves skin and present with significant functional and cosmetic outcome. Deep type includes intramuscular malformation and may have delayed presentation until subjected to infection and trauma (1-3).

Phlepoliths are defined as calcified thrombi and related to vascular malformations or hemangiomas produced by stasis of peripheral blood flow and are secondarily mineralized and enlarged (4). Phleboliths in head and neck region reported in both children and adults and commonly in the cheek. (5,6)

### **A Case Report:**

37 years old female presented to the outpatient clinic with left cheek swelling, chronic over all her age (as patient said since birth but it became noted by her family at an age of 4 to 5 years). It's increased in size over the 10 years ago; no history of trauma or other swelling in the body.

This swelling increased in size when the patient turns the head anteriorly or with the position.

Upon examination 3x5cm hard fixed cheek swelling externally and no evidence of skin discoloration, hotness, tenderness, abnormal bite or occlusion.

Intra oral examination revealed normal mucosa appearance, no discoloration or evidence of hematoma just deep seated mass lobulated mobile to fixed; no regional Lymphadenopathy ; other findings were unremarkable. Laboratory investigation all were within normal.

Patient underwent ultrasound and MRI of head and neck.

The treatment of choice for VM with phlebolith is surgical excision.

Both external and intra oral approaches discussed with the patient and the decision was extra oral approach. Considering the diffused nature of the malformation in the cheek with a high risk of

iatrogenic facial nerve injury and bleeding with surgery all this discussed with the patient and relatives.

Surgery was planned for excision of phleboliths, not VM because of diffused nature and potential risk of injure to the facial nerve.

We discussed the site for surgical incision because the swelling was nearly in mid face & medially and scar in such site becomes ugly. So the surgical incision as face lift incision ( pre auricular incision ).

It was decided that the tumor would be removed under general anesthesia. A face lift incision pre auricular was chosen to avoid unwanted scar formation. A skin and subcutaneous flap was raised through this incision until the anterior border of the left parotid gland. The parotid duct and buccal and zygomatic branches of the facial nerve were identified.

The gland was elevated from the masseter muscle and branches of the facial nerve were retrogradely dissected and preserved. The masses became palpable by deep seated palpation so the muscle fibers dissected Supero- posteriorly deep to the deep head of masseter muscle with careful dissection using microscopical Loup (5x) power, dissection continuous till multiple hard lobulated mass adherent significantly to muscle fibers that separated with difficulty reveal hard yellowish solid masses about 15-20s largest one about 6-5 cm & smaller one to 0-2 mm. after excision of masses secured hemostasis was done even that there was no significant bleeding or evidence for facial nerve branches injured at field. Approximation of muscle fibers by 5/0 Prolene: suture the wound with two layers, deep layer by 4/0 Vicryl and skin layer with 5/0 Prolene with sterri- strip dressing and bandage. Post operatively the patient started intravenous fluid, analgesia, antibiotics with dexamethasone for oedema. Then the patient started oral intake one day postoperatively with semisolid diet and examination revealed no evidence for any sensory or motor dysfunction including facial nerve palsy or impaired mastication. The masses were sent for histopathological examination which showed histological features of phleboliths (concentric lamellated calcification with central nidus)

## Discussion

Venous malformation (VM) of the head and neck are common condition that occurs due to abnormal vascular morphogenesis- Majority of (VM) occur in patient 15to 30 years of age with no Sex predilection .(7) signs and symptoms can be subtle depending on the site involved and extent of the lesion. (8). Various diagnostic modality has been used such as plain Radiographs where it will evaluate phleboliths, Duplex ultrasonic showing slow blood flow. C T scan will frequently demonstrate calcified phleboliths. MRI remains the modality of choice with the following characteristic T, Isointense T2 bright signal. (9) Post contrast diffuse in homogeneous enhancement.

The optimal treatment for VM would be complete excision of the lesion to avoid any recurrence (10). The accepted first line treatment of problematic VMs is sclera- therapy; but a palpable phlebolith remained unaffected by sclera therapy and could be an indicator for surgery. (11)

Wide treatment modalities available, the goal of cure can be obtained mainly in small focal lesions (12). These treatment options may be surgical to conservative therapy (laser or sclera therapy) depending on VMS type and patient presentation (13).

Regarding surgical intervention it can be done intra orally or extra- orally; but in this case extra-orally approach done with antegrade like face lift incisions for camouflage the surgical scar and preserve the major structures including facial nerve and parotid duct.

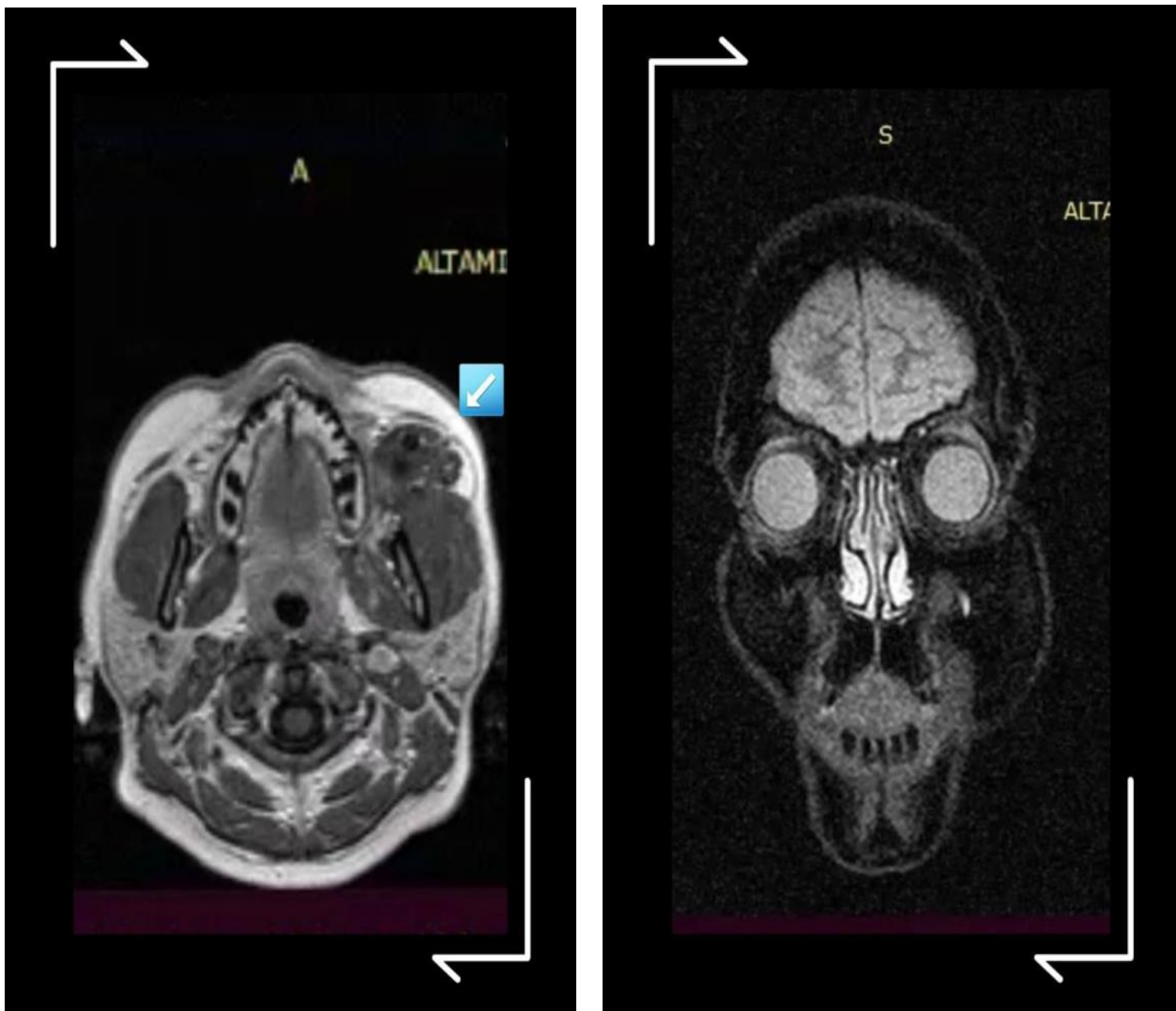


Figure (1)

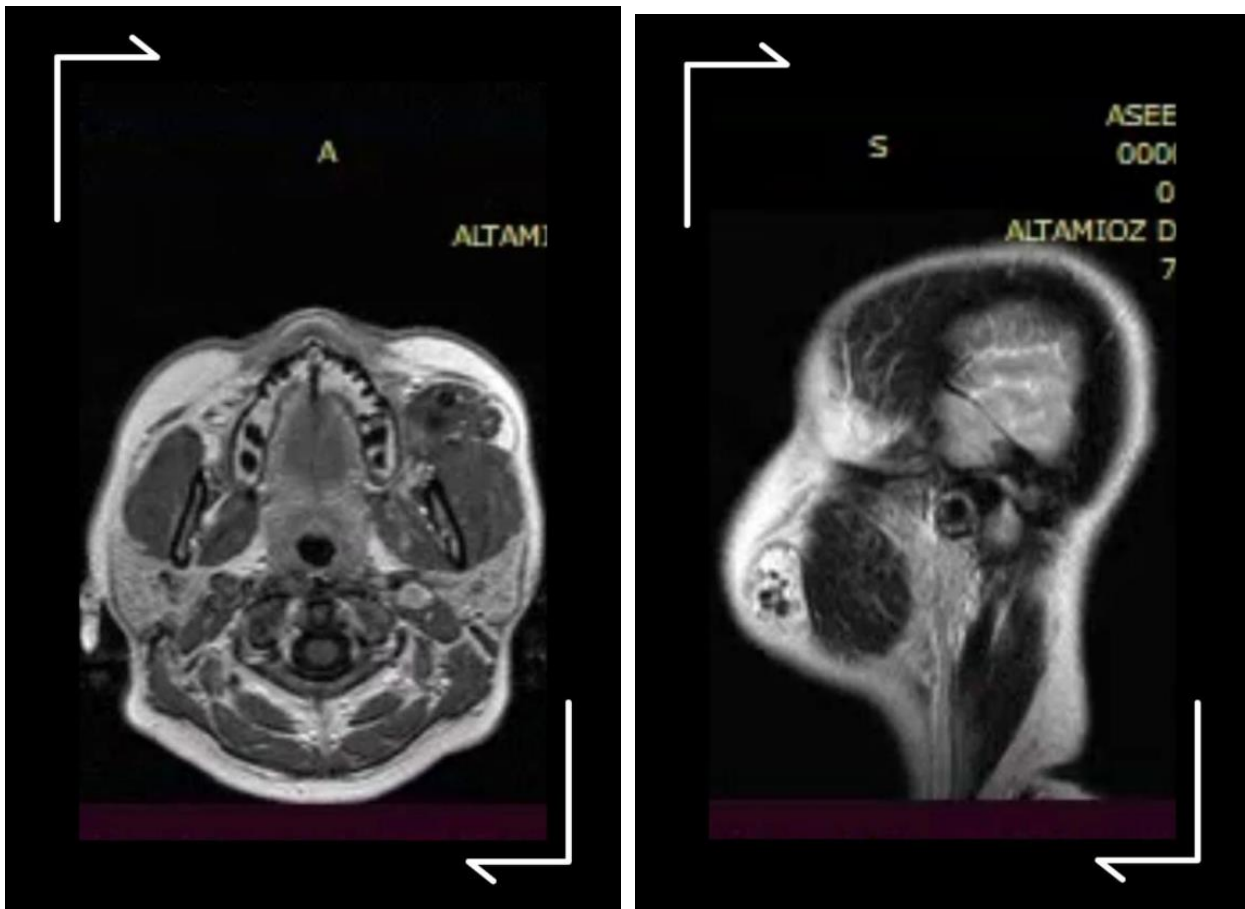


Figure (2): MRI for head reveal multiple tiny focus of fat with multiple hypointense rim calcifications .

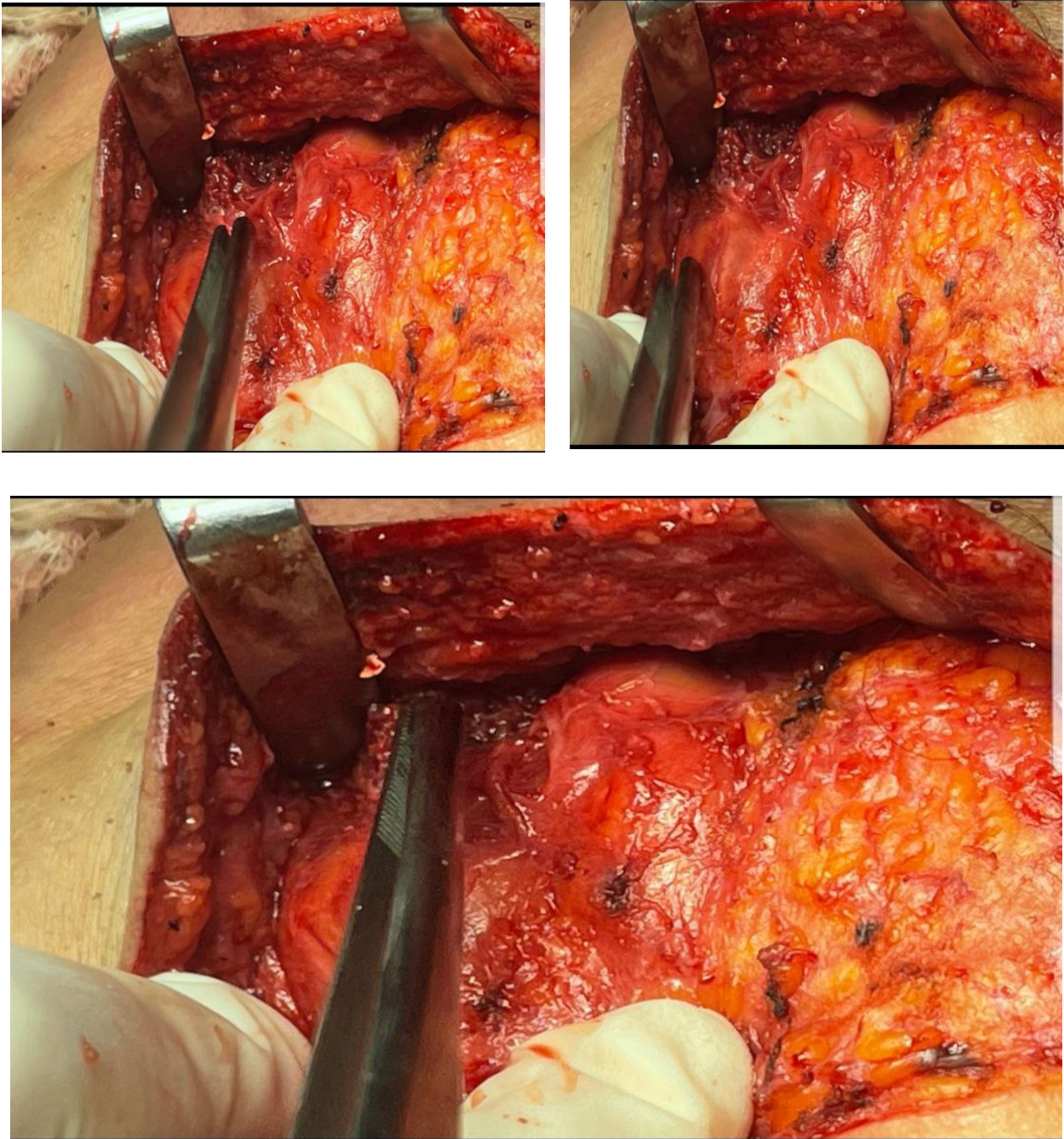


Figure (3): Intraoperative views show dissection deep with preservation of facial nerve branches till intramasseter dissection began with carefully till mass became obvious then freeing it from surrounding muscle fibers

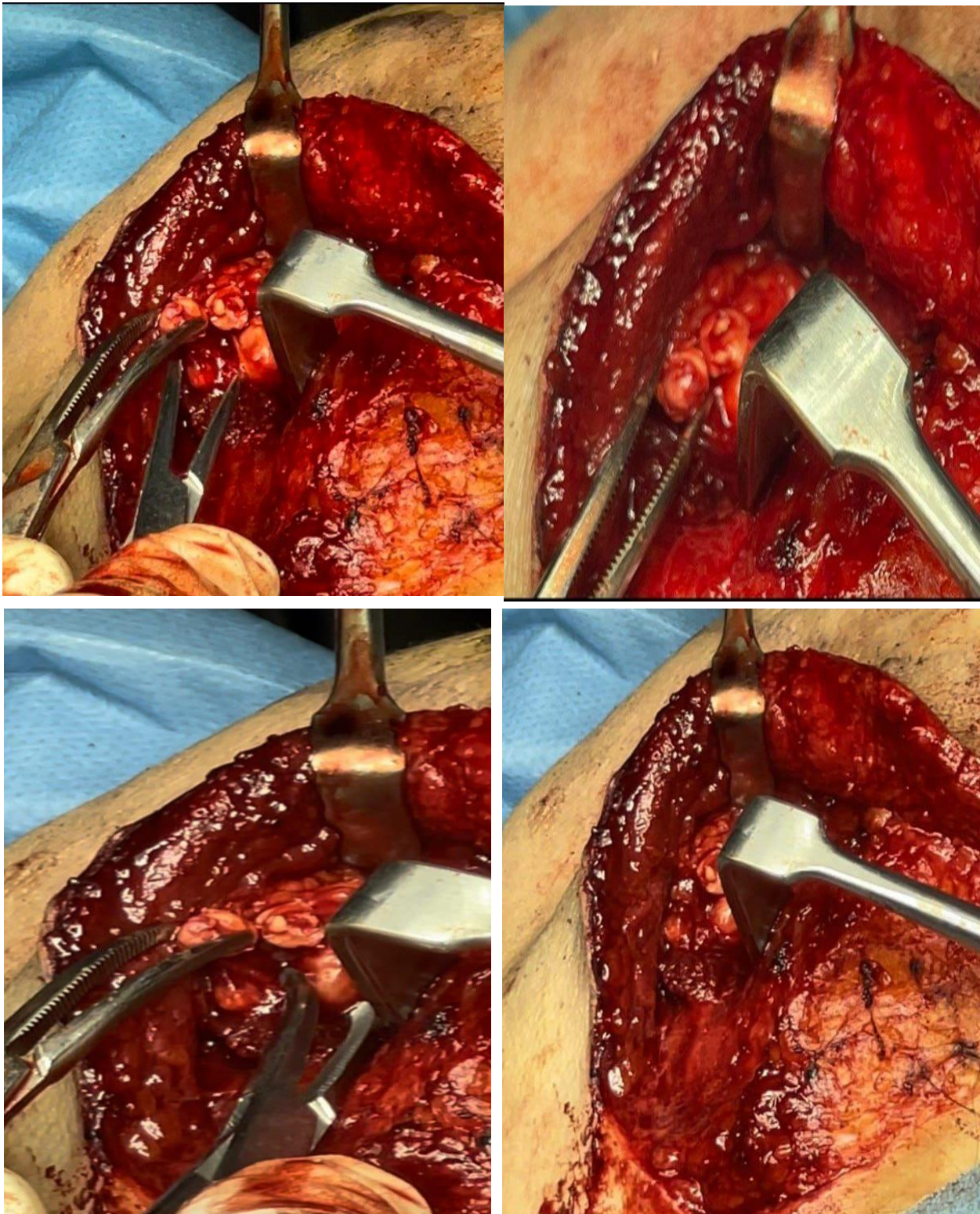


Figure (4)

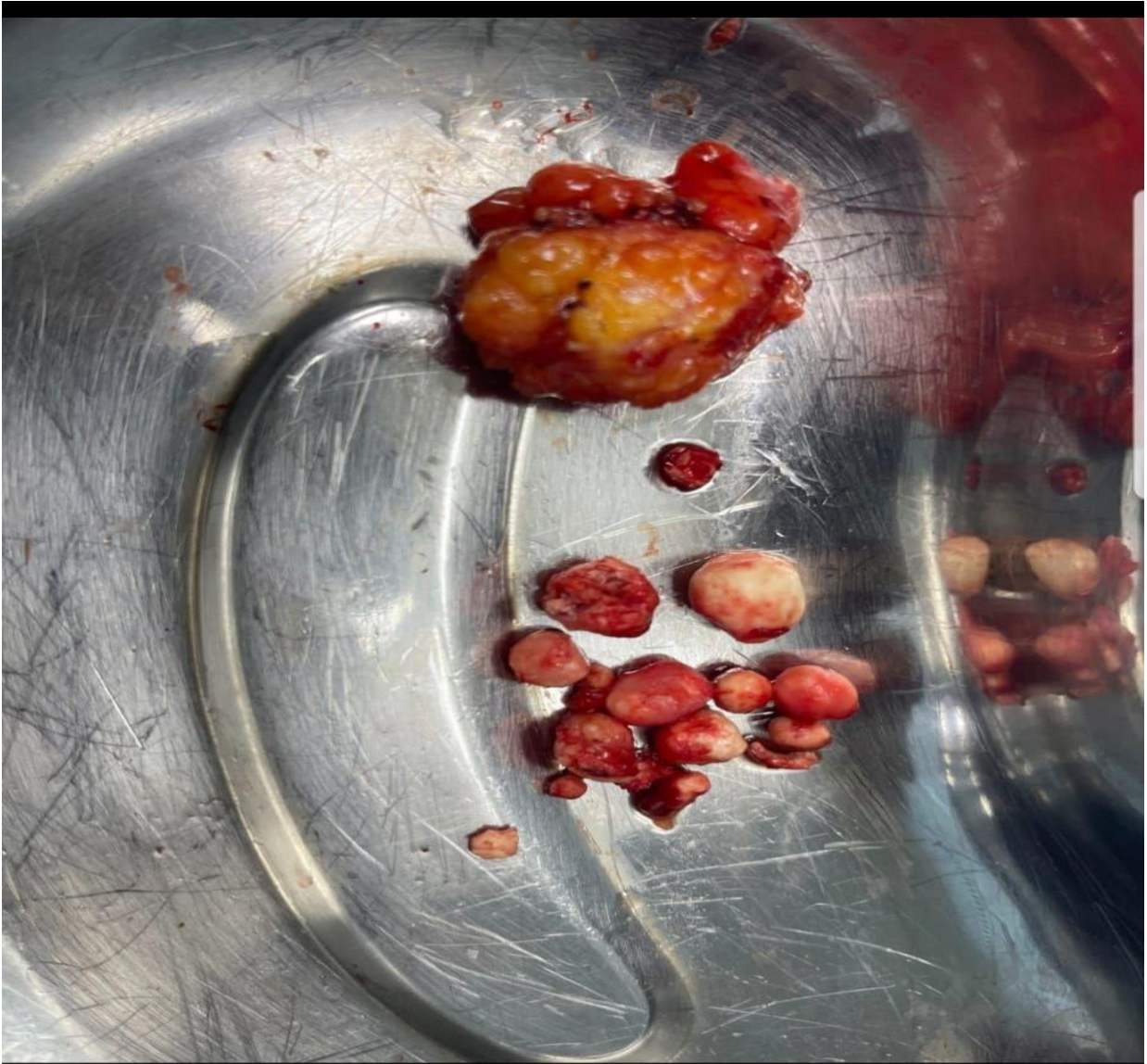

Figure (5): Tan soft to hard tissue with multiple stones.

### References:-

- 1- J.B. Mulliken, J. Glowacki Hemangiomas and vascular malformations in infants and children: a classification based on endothelial characteristics *Plast Reconstr Surg*, 69 (1982), p. 412
- 2- S. Russell, R.G. Watts, S.A. Royal, et al. Group A streptococcal infection of an intramuscular venous malformation: a case report and review of the literature *Pediatr Emerg Care*, 24 (2008), pp. 839-841

- 3- R.S. Glade, G.T. Richter, C.A. James, et al. Diagnosis and management of pediatric cervicofacial venous malformations: retrospective review from a vascular anomalies center Laryngoscope, 120 (2010), pp. 229-235
- 4- G. Anneroth, C.-M. Eneroth, G. Isacson Angiolithiasis in the parotid gland Int J Oral Surg, 7 (1978), p. 113
- 5- A.K. Raymond, J.G. Batsakis Angiolithiasis and sialolithiasis in the head and neck Onn Otol Rhinol Laryngol, 101 (1992), pp. 455-457
- 6- S.J. Morris, H. Adams Case report: paediatric intramuscular haemangioma-don't overlook the phlebolith Br J Radiol, 68 (1995), pp. 208-211
- 7- J.E. Scott Hemangiomas in skeletal muscle Br J Surg, 44 (1957), pp. 496-501
- 8- M. Waner, O. TM The role of surgery in the management of congenital vascular anomalies Tech Vasc Intervent Radiol, 16 (2013), pp. 45-50
- 9- W.P. Smith, S. Prince, S. Phelan The role of imaging and surgery in the management of vascular tumors of the masseter muscle J Oral Maxillofac Surg, 63 (2005), pp. 1746-1752
- 10- Rossiter JL, Hendrix RA, Tom LW, et al. Intramuscular hemangioma of the head and neck. Otolaryngol Head Neck Surg 1993;108:18-26.
- 11- Greene AK, Alomari AI. Management of venous malformations. Clin Plast Surg 2011;38:83-93.
- 12- J.W. Zheng, H.M. Mai, L. Zhang, et al. Guidelines for the treatment of head and neck venous malformations Int J Clin Exp Med, 6 (2013), pp. 377-389
- 13- H.L. Becker Masseteric muscle hypertrophy and its intra-oral surgical correction J Max Fac Surg, 5 (1977), pp. 28-35 .