

The Prevalence, Prediction and Angiographic Characteristics of Coronary Ectasia in Slemani Cardiac Center

Jamal Kareem Raheem*1

Dara Mohammed Mohialdeen2

Kawa Wsu Hassan 3

1 Slemani Cardiac Center, Slemani, Kurdistan Region-Iraq

2 Cardiology Bord Director in Slemani Cardiac Center/ Iraq

3 Slemani Cardiac Center, Slemani, Kurdistan Region-Iraq

***Corresponding author:**

Kareem255@gmail.com

Abstract

Background: Coronary artery ectasia (CAE) is an uncommon condition where a coronary artery becomes abnormally dilated. The present study was conducted in order to figure out the prevalence, prediction, and angiographic characteristics of coronary ectasia at the Sulaymaniyah Cardiac Center.

Materials and methods: The present cross-sectional study was conducted on 70 patients with coronary ectasia in in Sulaymaniyah cardiac center, Kurdistan region, Iraq from January to July 2022. Required data were gathered through the patients' medical files and coronary angiography reports. The collected data were analyzed via Statistical Package for Social Sciences (SPSS, version 24.0).

Results: Most of the patients (74.3%) were males. Most of them (80%) aged over 46 years. Acute coronary syndrome (ACS) and chronic coronary syndrome were found in 60% and 37.1% of the patients, respectively. Moreover, hypertension was observed in most of the patients (80%). The results revealed diffusion of two or more vessels (37.1%) and diffusion of only one vessel (31.4%) as the most frequent types of coronary ectasia. Classification of coronary ectasia was found to be significantly correlated with hypertension (p-value=0.004) but not with the patients' age, gender, chronic coronary syndrome, smoking, or diabetes mellitus (p-value>0.05).

Conclusion: The prevalence of coronary ectasia was found to be 3.3% among the studied population. Acute coronary syndrome was the most common presentation associated with CAE. Right artery was the most involved artery. Hypertension and smoking were found to be the most common risk factors for coronary ectasia.

Keywords: coronary ectasia, acute coronary syndrome, angiographic characteristics, coronary angiography

Introduction

Coronary artery ectasia (CAE) is an infrequent but recognized discovery observed during diagnostic coronary angiography. CAE is a relatively uncommon condition characterized by the dilation of the coronary artery lumen, referred to as "ectasia." In the case of CAE, "ectasia" denotes diffuse dilation, while the term "coronary aneurysm" is used to describe focal coronary dilation. Previous investigations have reported varying prevalence rates for CAE, ranging from 1.2% to 4.9%. The definition of coronary artery ectasia involves the presence of dilatation of over one-third of the coronary artery length, with the diameter of the dilated segment measuring more than 1.5 times the diameter of a regular adjacent segment (Qin et al., 2019). CAE can be categorized based on the shape and extent of involvement of the coronary arteries, with arterial aneurysm referring to focal dilatation and ectasia describing an elongated and expanded widening of a tubular structure (Devabhaktuni et al., 2016).

Although coronary angiography is considered the primary diagnostic method for identifying coronary artery ectasia (CAE), intravascular ultrasound is commonly employed to validate CAE morphology and luminal dilatation. In order to provide a more detailed classification of anatomical variations, Markis introduced a categorization system for CAE based on the extent of ectatic involvement. According to the classification presented in Table 1, the severity type ranges from Type I, which signifies diffuse ectasia affecting two or three vessels, to Type IV, indicating localized or segmental ectasia (Richards et al., 2022).

Table (1). Markis classification of coronary artery ectasia

Type	Description
I	Diffuse ectasia of two or three vessels
II	Diffuse disease in one vessel only and localized in another vessel
III	Diffuse disease in one vessel
IV	Localized or segmental ectasia

While there are some shared risk factors between coronary artery ectasia (CAE) and classical atherosclerotic heart disease (ASHD), CAE can also manifest independently without the presence of atherosclerotic stenotic arteries. This isolated occurrence of CAE can potentially result in turbulent blood flow and an increased risk of ischemic events. The clinical significance and appropriate management of CAE remain ill-defined due to the absence of randomized prospective studies. However, research has indicated that patients with both CAE and atherosclerotic heart disease exhibit a similar cardiovascular risk compared to those with atherosclerotic heart disease alone, whereas isolated CAE is associated with a favorable prognosis and a low risk of ischemic events (Brunetti et al., 2014). It is noteworthy that CAE patients with acute myocardial infarction who undergo percutaneous coronary intervention may encounter more complex procedures and a higher incidence of adverse events (Khanal et al., 2023).

The prevalence of coronary artery ectasia (CAE) among patients undergoing coronary angiography ranges from 0.3% to 5.3%. CAE can be incidentally detected in asymptomatic individuals during coronary angiography, such as those undergoing valve surgery or atrial fibrillation ablation. Additionally, CAE may be identified in the context of acute myocardial infarction (AMI) (ElGuindy et al., 2018). Clinical symptoms associated with CAE can arise from coexisting obstructive atherosclerotic disease or distal embolization caused by local thrombosis within a significantly dilated coronary segment. In patients presenting with AMI, the presence of CAE can impact procedural success and long-term outcomes (Matta et al., 2021).

In the existing literature, coronary artery ectasia (CAE) is a dilation exceeding 1.5 times the size of adjacent regular segments within the same or different arteries. It is a diffuse condition that needs to be distinguished from discrete aneurysms or localized dilations associated with conditions like Kawasaki disease. The etiology of CAE has been linked to various factors, including exposure to herbicides, Takayasu aortitis, polyarteritis nodosa, vascular trauma, and lesions. However, in the majority of cases, it appears to be associated with coronary arteriosclerosis. Patients with CAE typically present with coronary artery stenosis, angina, vasospasm, and myocardial infarction (Zhu et al., 2021). Coronary artery ectasia (CAE) encompasses a multifaceted clinical entity characterized by various presentations and an indeterminate prognosis. Despite several studies highlighting an elevated risk of unfavorable outcomes in patients with CAE and concomitant myocardial infarction, the management of CAE continues to pose challenges for clinical and interventional cardiologists (Baldi et al., 2022; Doi et al., 2017; Gunasekaran et al., 2019).

Due to the scarcity of studies and the rarity of the condition, a consensus regarding the treatment of coronary artery ectasia (CAE) is lacking. Individualized management approaches should be adopted based on whether patients have isolated CAE or CAE accompanied by obstructive coronary disease. Vigorous risk factor modification, involving the use of aspirin and statins, is essential for primary prevention. In complex cases, secondary prevention strategies such as anticoagulation and calcium channel blockers may be warranted (Patel et al., 2023). Patients experiencing angina symptoms may find relief through the use of beta-blockers and trimetazidine. For individuals with hypertension and coronary artery ectasia (CAE), ACE inhibitors are recommended as the primary approach. However, further investigation is required to evaluate the efficacy of modern antiplatelet and anticoagulant therapies in managing CAE. Tailoring treatment plans to each patient's specific clinical presentation and comorbidities is crucial. Developing evidence-based treatment strategies relies on ongoing monitoring and advancements in research (Khedr et al., 2021). The current study aims to examine the prevalence, prediction, and angiographic characteristics of coronary ectasia in Sulaymaniyah Cardiac Surgery Center.

Materials and methods

Study design and setting: The current cross-sectional study was conducted in Sulaymaniyah cardiac center, Kurdistan region, Iraq from January to July 2022.

Study sample and sampling method: The study sample consisted of 70 patients who were suffering from coronary ectasia diagnosed by coronary angiography. The inclusion criteria were patients who were between 18 and 80 years old, presence of angiographic evidence of coronary ectasia, and patients who gave informed consent. The exclusion criteria were age of below 18 and above 80 years, patients who refused to give informed consent, patients with coronary aneurysm, and those with previous history intervention for coronary arteries.

Data collection and analysis: During the study, 2100 cases underwent coronary angiography. This population was divided into two groups: patients with and patients without ectasia. Angiographic and clinical variables were studied in the second group. The patients' medical files were used, and the patients' coronary angiography reports were reviewed to collect required data. Statistical Package for Social Sciences (SPSS, version 24.0) was used to analyze the collected data. For this purpose, both descriptive and inferential statistics tests were employed.

Ethical considerations: The study's protocol was approved by the Ethics Committee of Kurdistan Board for Medical Specialty. Moreover, informed consent was obtained from the patients.

Results

According to the results, out of the 70 participating patients, 52 (74.3%) were males and the rest 18 patients (25.7%) were females. The patients' age ranged from 19 to over 66 years. Most of them (42.9%) aged from 46 to 65 years, 37.1% aged 66 years or more, and 20% aged 19 to 45 years. Moreover, acute coronary syndrome (ACS) was seen in 60% of them, and 37.1% had chronic coronary syndrome. A large number of the patients (60%) did not smoke. Also, hypertension (HTN) was detected in 80% of them, and 31.4% of them had diabetes mellitus (DM) (See Table 1).

Table (1). The patients' gender, age, and medical characteristics

	Frequency (N)	Percentage (%)
Gender		
Male	52	74.3
Female	18	25.7
Total	70	100.0
Age group		
19 - 45 early adult	14	20.0
46 - 65 mature adult	30	42.9
≥ 66 elderly	26	37.1
Total	70	100.0
ACS		
Yes	42	60.0
No	28	40.0
Total	70	100.0
Chronic coronary syndrome		
Yes	26	37.1
No	44	62.9
Total	70	100.0
Smoking		
Yes	28	40.0
No	42	60.0
Total	70	100.0
HTN		
Yes	56	80.0
No	14	20.0
Total	70	100.0
DM		
Yes	22	31.4
No	48	68.6
Total	70	100.0

Regarding the types of coronary ectasia, the results showed that 37.1% of the cases had two or more diffused vessels, 31.4% had one diffused vessel, 17.1% had one diffusion with two segments, and coronary ectasia was segmental in 14.3% of the cases (See Table 2 and Figure 1).

Table (2). Classification of coronary ectasia

Classification of coronary ectasia		
Diffusion of two or more vessels	26	37.1
One diffusion with two segments	12	17.1
Only one vessel diffusion	22	31.4
Segmental	10	14.3
Total	70	100.0

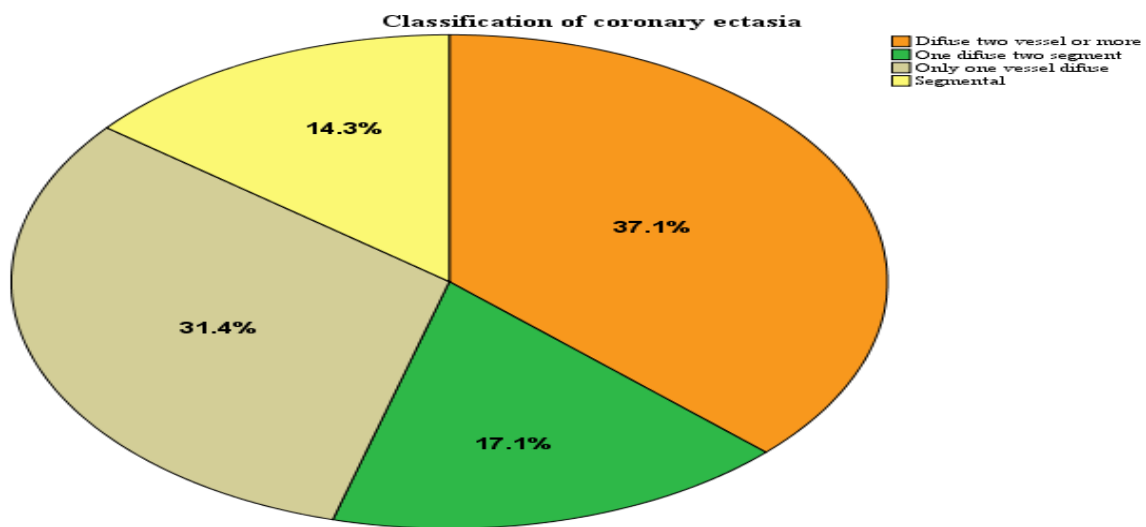


Figure (1). Classification of coronary ectasia

Analyzing the relationship between the studied variables revealed that classification of coronary ectasia had no significant correlation with the patients' gender or smoking status (p -value >0.05). Moreover, there were not any significant correlations between classification of coronary ectasia and chronic coronary syndrome or diabetes mellitus (p -value >0.05). However, the classification of coronary ectasia was found to be significantly correlated with hypertension (p -value=0.004) (See Table 3).

Table (3). Relationship between the studied variables

Variable					P-value
Gender		Male	Female	Total	0.531
Classification of coronary ectasia	Diffusion of two or more vessels	20(76.90)	6(23.1)	26(100.0)	
	One diffusion with two segments	8(66.7)	4(33.3)	12(100.0)	
	Only one diffused vessel	18(81.8)	4(18.2)	22(100.0)	
	Segmental	6(60.0)	4(40.0)	10(100.0)	
Total		52(74.3)	18(25.7)	70(100.0)	
Chronic coronary syndrome		Yes	No	Total	0.870
Classification of coronary ectasia	Diffusion of two or more vessels	14(53.8)	12(46.2)	26(100.0)	
	One diffusion with two segments	8(66.7)	4(33.3)	12(100.0)	
	Only one diffused vessel	14(63.6)	8(36.4)	22(100.0)	
	Segmental	6(60.0)	4(40.0)	10(100.0)	
Total		42(60.0)	28(40.0)	70(100.0)	
Smoking		Yes	No	Total	0.591
Classification of coronary ectasia	Diffusion of two or more vessels	12(46.2)	14(53.8)	26(100.0)	
	One diffusion with two segments	4(33.3)	8(66.7)	12(100.0)	
	Only one diffused vessel	6(27.3)	16(72.7)	22(100.0)	
	Segmental	4(40.0)	6(60.0)	10(100.0)	
Total		26(37.1)	44(62.9)	70(100.0)	
HTN		Yes	No	Total	0.004
Classification of coronary ectasia	Diffusion of two or more vessels	10(38.5)	16(61.5)	26(100.0)	
	One diffusion with two segments	0(0.0)	12(100.0)	12(100.0)	
	Only one diffused vessel	12(54.5)	10(45.5)	22(100.0)	
	Segmental	6(60.0)	4(40.0)	10(100.0)	
Total		28(40.0)	42(60.0)	70(100.0)	
DM		Yes	No	Total	0.074
Classification of coronary ectasia	Diffusion of two or more vessels	24(92.3)	2(7.7)	26(100.0)	
	One diffusion with two segments	8(66.7)	4(33.3)	12(100.0)	
	Only one diffused vessel	18(81.8)	4(18.2)	22(100.0)	
	Segmental	6(60.0)	4(40.0)	10(100.0)	
Total		56(80.0)	14(20.0)	70(100.0)	

According to the results, the classification of coronary ectasia had no significant correlation with the patient's age (p-value=0.574) (See Table 4).

Table (4). Relationship between classification of coronary ectasia and patients' age

		Age group			Total	P-value
		19 - 45 early adult	46 - 65 mature adult	≥ 66 elderly		
Classification of coronary ectasia	Diffusion of two or more vessels	6(23.1)	12(46.2)	8(30.8)	26(100.0)	0.574
	One diffusion with two segments	2(16.7)	4(33.3)	6(50.0)	12(100.0)	
	Only one diffused vessel	6(27.3)	8(36.4)	8(36.4)	22(100.0)	
	Segmental	0(0.0)	6(60.0)	4(40.0)	10(100.0)	
Total		14(20.0)	30(42.9)	26(37.1)	70(100.0)	

Discussion

The findings indicate that the study cohort primarily consisted of male individuals in the middle-aged to elderly range. The majority of participants presented with acute coronary syndrome and hypertension, while approximately one-third had diabetes. Smoking prevalence was relatively low. The age and gender distribution of the cohort align with the typical demographic profile observed in cases of coronary artery disease. The high prevalence of hypertension and diabetes is consistent with their recognized status as risk factors for cardiovascular ailments. The predominance of acute coronary syndrome underscores the importance of continuous monitoring and preventive care in this older patient population, which is particularly susceptible to recurrent cardiac events. Consistent with the findings of the present study, Flood et al. (2022) demonstrated that hypertension and diabetes are two significant cardiovascular disease (CVD) risk factors that can be modified through shared pathophysiology and clinical strategies. Effective identification, treatment, and management of hypertension and diabetes can significantly reduce mortality and disability associated with CVD. Furthermore, previous research has documented that coronary artery ectasia (CAE) refers to a condition characterized by abnormal dilation of a segment of a coronary artery, reaching at least 1.5 times the size of an adjacent normal coronary artery (Damay et al., 2019). Coronary artery ectasia (CAE) is a rare manifestation of coronary heart disease characterized by the abnormal dilation of coronary arteries, which poses an increased risk of angina pectoris and acute coronary syndrome (ACS). It is estimated to be present in 3-8% of patients undergoing coronary angiography (CAG). The ectatic enlargement of the coronary arteries can potentially contribute to the development of ACS (Khedr et al., 2021). In a separate study conducted by Bahremand et al. (2021), the association between CAE and hypertension (HTN) remains unclear in terms of pathophysiology and causality. However, CAE is frequently observed in patients with conditions such as atherosclerosis, connective tissue disorders, and heightened inflammatory responses.

The findings indicated that the most prevalent subtype of coronary ectasia was diffuse involvement of multiple vessels, although localized single-vessel and segmental variations were also observed. In contrast to the data obtained in this study, the prevalence of coronary artery aneurysm and coronary artery ectasia in the general population remains unknown, as reported by Kawsara et al. (2018). However, several studies have reported the occurrence rates of both phenotypes among patients referred for coronary angiography due to various clinical indications. While coronary artery ectasia is documented in up to 5% of coronary angiograms, true coronary artery aneurysms are less commonly observed (Luo et al., 2017; Núñez-Gil et al., 2018). The diffuse subtype of coronary ectasia was predominant in this study, which aligns with the findings of Willner et al. (2020) who also reported the diffuse subtype as the most prevalent. However, there were differences in the rates of isolated coronary artery ectasia (CAE) versus mixed CAE and atherosclerotic disease between our cohort and that of Willner et al. Notably, our cohort had lower rates of isolated CAE. Both studies observed involvement of the right coronary artery. The inconsistent rates of isolated and mixed CAE highlight the need for further investigation into how coexisting atherosclerosis may influence the pathogenesis and outcomes of CAE. More comprehensive studies are required to compare the morphology of CAE, the affected vessels, and clinical factors such as atherosclerosis to elucidate the variable presentations of this disease.

The results suggest that factors such as gender, smoking status, chronic coronary syndrome, and diabetes mellitus did not show a significant association with the classification of coronary ectasia. However, hypertension demonstrated a significant correlation, indicating that it may serve as a crucial risk factor influencing the severity of coronary ectasia. Nevertheless, further comprehensive prospective studies are required to validate this relationship and provide insights into the underlying pathophysiology. The findings underscore the importance of adequately managing hypertension in patients diagnosed with coronary ectasia. As mentioned previously, Bahremand et al. (2021) conducted a similar study and found that hypertension (HTN) did not significantly increase the likelihood of coronary artery ectasia (CAE) when the coronary vessels were in a normal condition. However, when other risk factors resulted in abnormal vessel conditions, HTN increased the chances of CAE by 44%. When adjusting for confounding factors, the effect of HTN on CAE risk only increased by 3%. On the other hand, Esposito et al. (2021) reported that hypertension, smoking, dyslipidemia (including familial hypercholesterolemia), have been associated with CAE. In contrast, Zografos et al. (2014) noted that diabetes mellitus has an inverse relationship with CAE compared to coronary artery disease (CAD). This discrepancy may be explained by the adverse remodeling of the artery wall promoted by diabetes mellitus, which impairs compensatory vessel enlargement and potentially contributes to the lower prevalence of CAE in diabetic patients.

The findings revealed that there was no significant association between patient age and the classification of coronary ectasia. In a comparable study, Huang et al. (2014) mentioned that coronary artery ectasia (CAE) is often considered a variant of coronary artery atherosclerosis; however, a definitive connection has not yet been established. Aging is a well-established risk factor for coronary artery disease, but the relationship between aging and CAE remains poorly

understood. Extensive studies have demonstrated an inverse association between age and the incidence of CAE (Giannoglou et al., 2006; Pinar et al., 2003). If the progression of coronary artery ectasia (CAE) is gradual, patients may experience a longer duration of the disease than what is commonly presumed. Although the average age of diagnosis for CAE is in the mid-fifties, ectatic changes in the coronary arteries can occur at younger ages as well. The study indicates a stronger association between CAE and genetic factors in cases of early-onset CAE that do not involve other known risk factors such as Kawasaki disease or prior interventions. However, additional research is needed to investigate potential genetic influences on the pathology and progression of CAE in individuals diagnosed at a younger age.

Conclusion

In summary, this study examined a cohort of 70 patients and identified a high prevalence of coronary ectasia among older males who had comorbidities such as hypertension. Although, smoking and diabetes did not show a significant association with coronary ectasia, they are also important risk factors. The most common presentation of the condition was acute coronary syndrome. The study found that diffuse multi-vessel involvement was the most prevalent, affecting more than two-thirds of the patients. These findings indicate that coronary ectasia primarily affects older men with hypertension and is commonly manifested as acute coronary syndrome with involvement of multiple vessels. Age, gender, smoking status, diabetes, and chronic symptoms did not appear to be correlated with the classification of ectasia. However, hypertension showed a correlation with a more extensive disease pattern. It is recommended that further research with larger sample sizes be conducted to confirm hypertension as a risk factor for diffuse multi-vessel ectasia.

References

- Bahreman, M., Zereshki, E., Matin, B. K., Rezaei, M., & Omrani, H. (2021). Hypertension and coronary artery ectasia: a systematic review and meta-analysis study. *Clinical Hypertension*, 27(1), 14. <https://doi.org/10.1186/s40885-021-00170-6>.
- Baldi, C., Silverio, A., Esposito, L., Di Maio, M., Tarantino, F., De Angelis, E., ... Galasso, G. (2022). Clinical outcome of patients with ST-elevation myocardial infarction and angiographic evidence of coronary artery ectasia. *Catheterization and Cardiovascular Interventions: Official Journal of the Society for Cardiac Angiography & Interventions*, 99(2), 340–347. doi:10.1002/ccd.29738.
- Brunetti, N. D., Salvemini, G., Cuculo, A., Ruggiero, A., De Gennaro, L., Gaglione, A., & Di Biase, M. (2014). Coronary artery ectasia is related to coronary slow flow and inflammatory activation. *Atherosclerosis*, 233(2), 636–640. doi:10.1016/j.atherosclerosis.2014.01.018.
- Damay, V., Pranata, R., & Wiharja, W. (2019). Recurrent acute coronary syndrome in a patient with right coronary artery ectasia: a case report. *Journal of Medical Case Reports*, 13(1). <https://doi.org/10.1186/s13256-019-1979-x>.

- Devabhaktuni, S., Mercedes, A., Diep, J., & Ahsan, C. (2016). Coronary artery ectasia-A- A review of current literature. *Current Cardiology Reviews*, 12(4), 318–323. doi:10.2174/1573403x12666160504100159.
- Doi, T., Kataoka, Y., Noguchi, T., Shibata, T., Nakashima, T., Kawakami, S., ... Yasuda, S. (2017). Coronary artery ectasia predicts future cardiac events in patients with acute myocardial infarction. *Arteriosclerosis, Thrombosis, and Vascular Biology*, 37(12), 2350–2355. doi:10.1161/atvbaha.117.309683.
- ElGuindy, M. S., & ElGuindy, A. M. (2018). Aneurysmal coronary artery disease: An overview. *Global Cardiology Science & Practice*, 2017(3). doi:10.21542/gcsp.2017.26.
- Esposito, L., Di Maio, M., Silverio, A., Cancro, F. P., Bellino, M., Attisano, T., Tarantino, F. F., Esposito, G., Vecchione, C., Galasso, G., & Baldi, C. (2021). Treatment and outcome of patients with coronary artery ectasia: Current evidence and novel opportunities for an old dilemma. *Frontiers in Cardiovascular Medicine*, 8, 805727. <https://doi.org/10.3389/fcvm.2021.805727>.
- Flood, D., Edwards, E. W., Giovannini, D., Ridley, E., Rosende, A., Herman, W. H., Jaffe, M. G., & DiPette, D. J. (2022). Integrating hypertension and diabetes management in primary health care settings: HEARTS as a tool. *Revista Panamericana de Salud Publica [Pan American Journal of Public Health]*, 46, e150. <https://doi.org/10.26633/RPSP.2022.150>.
- Giannoglou, G. D., Antoniadis, A. P., Chatzizisis, Y. S., Damvopoulou, E., Parcharidis, G. E., & Louridas, G. E. (2006). Prevalence of ectasia in human coronary arteries in patients in northern Greece referred for coronary angiography. *The American Journal of Cardiology*, 98(3), 314–318. <https://doi.org/10.1016/j.amjcard.2006.02.034>.
- Gunasekaran, P., Stanojevic, D., Drees, T., Fritzen, J., Haghnegahdar, M., McCullough, M., ... Gupta, K. (2019). Prognostic significance, angiographic characteristics and impact of antithrombotic and anticoagulant therapy on outcomes in high versus low grade coronary artery ectasia: A long-term follow-up study. *Catheterization and Cardiovascular Interventions: Official Journal of the Society for Cardiac Angiography & Interventions*, 93(7), 1219–1227. doi:10.1002/ccd.27929.
- Huang, Q.-J., Zhang, Y., Li, X.-L., Li, S., Guo, Y.-L., Zhu, C.-G., Xu, R.-X., Jiang, L.-X., Chen, M.-H., & Li, J.-J. (2014). Clinical features of coronary artery ectasia in the elderly. *Journal of Geriatric Cardiology: JGC*, 11(3), 185–191. <https://doi.org/10.11909/j.issn.1671-5411.2014.03.012>.
- Kawsara, A., Núñez Gil, I. J., Alqahtani, F., Moreland, J., Rihal, C. S., & Alkhouli, M. (2018). Management of coronary artery aneurysms. *JACC. Cardiovascular Interventions*, 11(13), 1211–1223. <https://doi.org/10.1016/j.jcin.2018.02.041>.
- Khanal, S., Choudhary, A. K., & Kumar, B. (2023). A case report of high-risk percutaneous coronary intervention of left main coronary artery with cardiogenic shock. *Cureus*. doi:10.7759/cureus.41983.
- Khedr, A., Neupane, B., Proskuriakova, E., Jada, K., Kakieu Djossi, S., & Mostafa, J. A. (2021). Pharmacologic management of coronary artery ectasia. *Cureus*. doi:10.7759/cureus.17832.
- Khedr, A., Neupane, B., Proskuriakova, E., Jada, K., Kakieu Djossi, S., & Mostafa, J. A. (2021). Pharmacologic management of coronary artery ectasia. *Cureus*, 13(9), e17832. <https://doi.org/10.7759/cureus.17832>.
- Liu, R., Zhao, H., Gao, X., & Liang, S. (2021). Is coronary artery ectasia a progressive disease? A self-controlled retrospective cohort study. *Frontiers in Cardiovascular Medicine*, 8, 774597. <https://doi.org/10.3389/fcvm.2021.774597>.
- Luo, Y., Tang, J., Liu, X., Qiu, J., Ye, Z., Lai, Y., Yao, Y., Li, J., Wang, X., & Liu, X. (2017). Coronary artery aneurysm differs from coronary artery ectasia: Angiographic characteristics and cardiovascular

- risk factor analysis in patients referred for coronary angiography. *Angiology*, 68(9), 823–830. <https://doi.org/10.1177/0003319716665690>.
- Matta, A. G., Yaacoub, N., Nader, V., Moussallem, N., Carrie, D., & Roncalli, J. (2021). Coronary artery aneurysm: A review. *World Journal of Cardiology*, 13(9), 446–455. doi:10.4330/wjc.v13.i9.446.
- Núñez-Gil, I. J., Terol, B., Feltes, G., Nombela-Franco, L., Salinas, P., Escaned, J., Jiménez-Quevedo, P., Gonzalo, N., Vivas, D., Bautista, D., Macaya, C., & Fernández-Ortiz, A. (2018). Coronary aneurysms in the acute patient: Incidence, characterization and long-term management results. *Cardiovascular Revascularization Medicine: Including Molecular Interventions*, 19(5 Pt B), 589–596. <https://doi.org/10.1016/j.carrev.2017.12.003>.
- Patel, P., Shrivastava, R., Patel, R., & Warghane, P. (2023). Coronary artery ectasia. *Indian Journal of Clinical Cardiology*, 4(1), 30–38. doi:10.1177/26324636231157469.
- Pinar, B. E., López, P. R., Lozano, M.-L. I., Cortés, S. R., Carrillo Sáez P, Rodríguez, C. R., Picó, A. F., & Valdés, C. M. (2003). [Coronary ectasia: prevalence, and clinical and angiographic characteristics]. *Revista Espanola de Cardiologia*, 56(5). [https://doi.org/10.1016/s0300-8932\(03\)76902-4](https://doi.org/10.1016/s0300-8932(03)76902-4).
- Qin, Y., Tang, C., Ma, C., & Yan, G. (2019). Risk factors for coronary artery ectasia and the relationship between hyperlipidemia and coronary artery ectasia. *Coronary Artery Disease*, 30(3), 211–215. doi:10.1097/MCA.0000000000000709.
- Richards, G. H. C., Hong, K. L., Henein, M. Y., Hanratty, C., & Boles, U. (2022). Coronary artery ectasia: Review of the non-atherosclerotic molecular and pathophysiologic concepts. *International Journal of Molecular Sciences*, 23(9), 5195. doi:10.3390/ijms23095195.
- Willner NA, Ehrenberg S, Musallam A, et al. (2020). Coronary artery ectasia: prevalence, angiographic characteristics and clinical outcome *Open Heart* 2020;7:e001096. doi: 10.1136/openhrt-2019-001096.
- Zhu, X., Zhou, Q., Tong, S., & Zhou, Y. (2021). Challenges and strategies in the management of coronary artery aneurysms. *Hellenike Kardiologike Epitheorese [Hellenic Journal of Cardiology]*, 62(2), 112–120. doi:10.1016/j.hjc.2020.09.004.
- Zografos, T. A., Korovesis, S., Giazitzoglou, E., Kokladi, M., Venetsanakos, I., Paxinos, G., Fragakis, N., & Katritsis, D. G. (2013). Clinical and angiographic characteristics of patients with coronary artery ectasia. *International Journal of Cardiology*, 167(4), 1536–1541. <https://doi.org/10.1016/j.ijcard.2012.04.098>.