

A Giant Cerebral Hydatid Cyst Required Urgent Operation: Case Report

Amjed Hassan Saheb, M.D. Department of Neurosurgery, AL-Husain Teaching Hospital, Thi-Qar, Iraq

Firas Abdullah Noori, FIBMS-DR, lecturer, Thi-Qar University / College of Medicine

KEYWORDS

Brain hydatid cyst, Echinococcus granulosus, Dowling-Orlando technique.

Introduction

We report our experience with a rare case of brain hydrated cyst which required urgent surgery because of the life threatening elevation of intra cranial pressure(ICP) . Totally removal of the cyst en block was achieved, and the resumed his daily activity without neurological deficit. Brain hydrated cyst is usually treated by scheduled operations ,but it may develop an emergent status in the involved patient .Immediate decompressive surgery by en block removal of the lesion Following minimum clinical investigations are recommended in any operations.

CASE REPORT

26 years old man from rural area, in the south of Iraq, was admitted to Our emergency room with signs of increased intracranial pressure. Glasgow coma scale GCS was 11/15 (E3V3M4), there are no

sensorimotor deficit , fundoscopic examination revealed right dominant bilateral papilledema. An interview to his family, revealed that patient start the deterioration since 2 days ago, but he had complaining headache since 3 months ago, and the symptoms had been gradually worsening.

Patient family also mentioned that he was drink water directly from

river, and unpasteurized milk. Routine blood tests, chest X-ray, abdominal ultrasonography were unremarkable. A computed tomography (CT) of the brain(FIG 1) revealed very large cystic lesion in his right temporo-parietal region, which was well demarcated , isodensity with cerebrospinal fluid, and causing marked mass effect.

Magnetic resonance imaging (MRI)could not be done because of emergency. The Patient immediately underwent surgery via a large right temporo – parietal craniotomy, with very careful attention not to lacerate dura due to chronic high intracranial pressure, because dural laceration may cause rupture of the cyst. Cortical incision was about 2/3 of the cyst diameter. After opening the thin cortical layer covered the cyst with low power bipolar cautery ,the surface of the cyst was exposed.

Total removal of the cyst was done by Dowling-Orlando technique(fig2a),and cyst was removed without rupture (fig 2 b). Histopathological study of the cyst revealed Echinococcus granulosus (fig 3)and the diagnosis of hydated cyst was confirmed . The patient resumed his daily activity, and was discharged 10 days after the operation without complications.

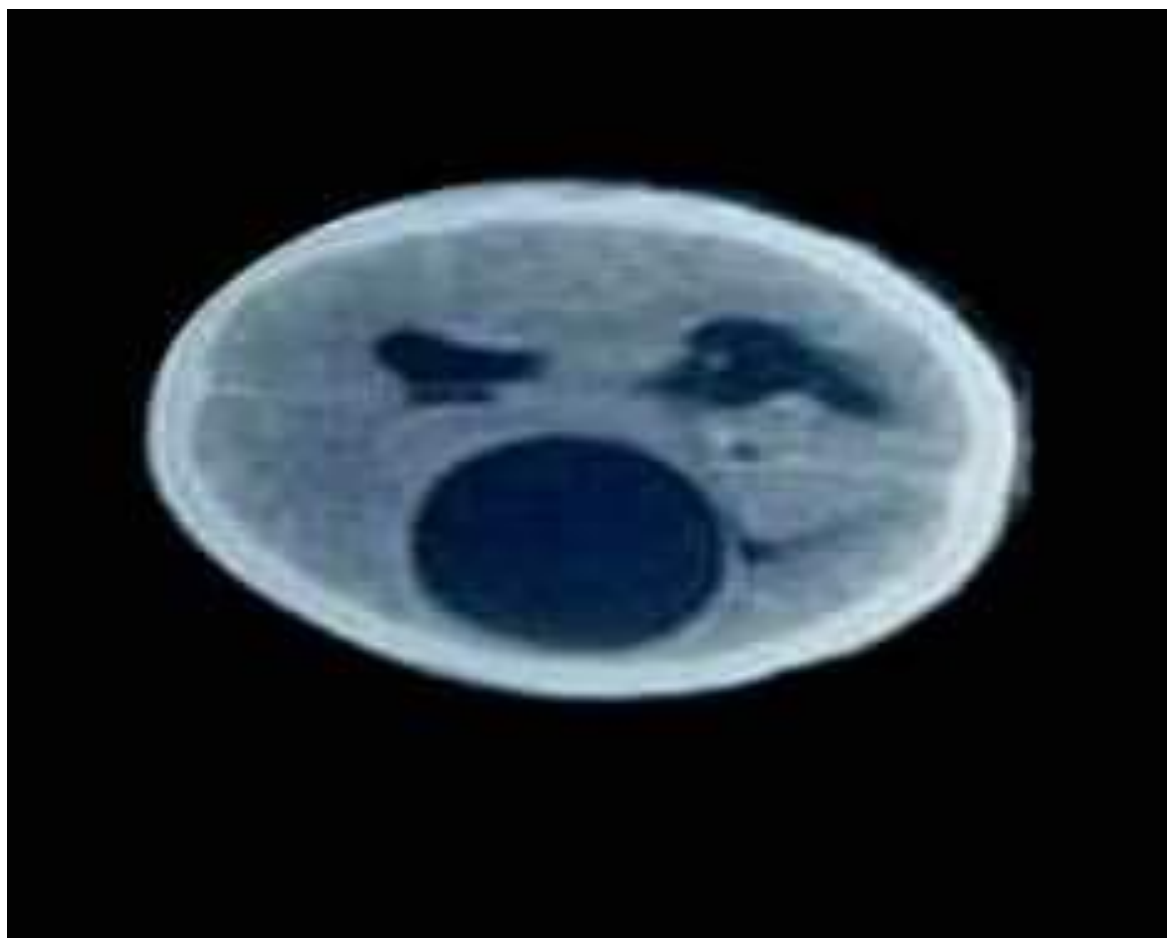

FIG .1: computed tomography (CT) scan showing a very large the right temporo - parietal region of the patient. The cyst is well demarcated , isodense with cerebrospinal fluid ,and causing marked mass effect.

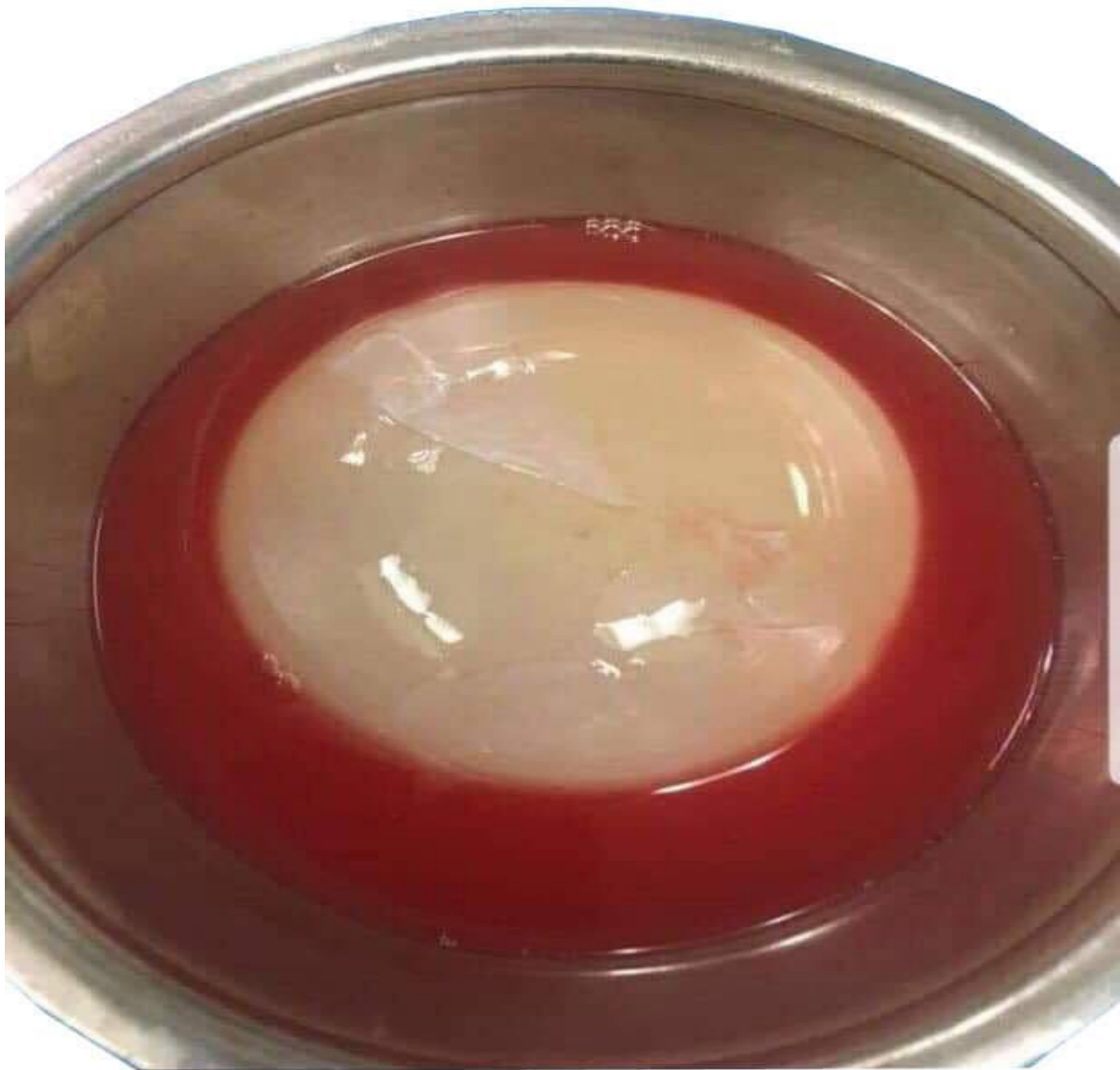

FIG .2: Intraoperative picture showing the exposed hydrated cyst (a),and totally removed cyst without rupture(b).

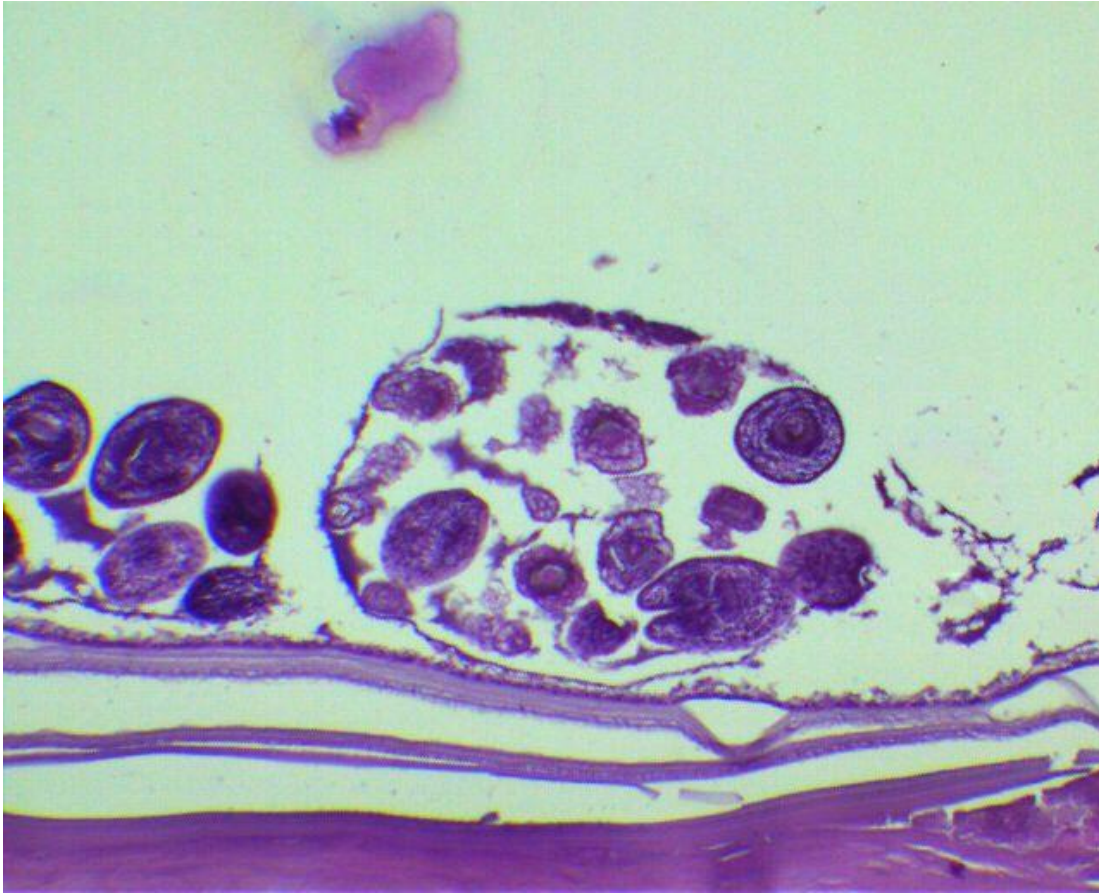


FIG 3: Representative histopathological study of cyst removed is echinococcus granulosus, stained with hematoxylin and eosin(H&E)

DISCUSSION

Echinococcus granulosus is a small tapeworm, live in the small intestine of canids as an adult (definitive host), dog feces are contaminated with eggs, then ingested by cattle and sheep.(1) Digestion of capsule occur after eating contaminated food, then

embryos penetrate intestinal human mucosa, and spread through portal circulation system. liver and lung are most common human organs and invasion of brain is rare, even in endemic area, it I incidances just about 1-2% from all brain space occupying

lesion. Infected organs are usually multiple at same time, therefore complete radiological evaluation of the whole body is recommended (2). Isolated brain hydatid cyst is very rare, and only a few reports from the endemic area, such as middle east and India, are available(7,8)to date. Cerebral hydatid cyst require special anatomical conditions, to allow the germ to shunt the filter of both hepatic and pulmonary circulatory systems. Most frequent distribution is the region of the middle cerebral artery and its branches(12).The cysts might be multiples, due to embolization of multiple original larva, trauma, iatrogenic, or spontaneous cyst rupture(14,15) There is usually no specific clinical presentation , and signs of elevated ICP, depending on location and size and focal signs and seizure are rare. Ersahin et al reported a growth rate about 1 cm- month(16). Serological test does not usually reveal anything special, but eosinophilia is present in 25% of involved patients . MRI study and scan are the most important in the diagnosis and surgical (13). The cyst usually presents as a solitary(usually), homogeneous, spherical lesion with well-demarcated borders, usually without enhancement, and

usually without surrounding edema. All differential diagnosis of cystic lesions (such as arachnoid cysts, cystic tumors, abscess, and porencephalic cysts) should always be considered (19). Advanced imaging techniques, such as diffusion tensor imaging(DTI) or MR spectroscopy, are not conclusive but can be helpful.

The goal of surgery is en block removal of the entire cyst (en block) without rupture, to prevent parasitic spread to cause further neurological deficits, or anaphylactic reaction which may be some times fatal(3,20). Insert a soft rubber catheter between cyst and brain, Continuous warm saline irrigation between the cyst and the surrounding brain parenchyma to help delivery (Dowling's –orlando technique) is recommended.

Rupture of the cyst significantly increase cyst recurrence, and parasite spread to distant site(21,22). In case of cyst rupture, the fluid content should be aspirated immediately by putting suction tube inside the cyst, and placing 10% formalin soaked cottonoid , and continuous saline

irrigation for about 5 minutes, after the removal of the capsule (23).

Postoperative treatment with 400mg of albendazole intake should be started immediately after the operation, and should be continued for about 8 months.(26).

CONCLUSION

Rural areas in some parts of middle east are still endemic with hydatid cyst ,and this clinical

entity should be included in the differential diagnosis for any patient coming from an endemic country who present with an cerebral cyst. Early diagnosis and complete surgical cyst removal are the most important factors that determine the outcome of involved patient .The best surgical technique is en bloc removal of the cyst. Cyst puncture is contraindicated because of the possible aggravation of the patient condition

REFEFENCES

1. Ozdemir NG, Kurt A, Binici DN, Ozsoy KM. *Echinococcus alveolaris*: Presenting as a cerebral metastasis. Turk Neurosurg. 2012;22(4):448–51.
2. Kizilca O, Altas M, Senol U, Oztek MA. Hydatid disease located in the cerebellomedullary cistern. Case Rep Med. 2014;2014:271365. [
3. Richter J, Profis E, Holtfreter MC, et al. Anaphylactic shock ensuing therapeutic puncture of an echinococcal cyst. Parasitol Res. 2015;114(2):763–66.
4. Turgut M. Hydatidosis of central nervous system and its coverings in the pediatric and adolescent age groups in Turkey during the last century: A critical review of 137 cases. Childs Nerv Syst. 2002;18(12):670–83.
5. Carrea R, Dowling E, Jr, Guevara JA. Surgical treatment of hydatid cysts of the central nervous system in the pediatric age (Dowling's technique) Childs Brain. 1975;1(1):4–21.]
6. Dowling EO. Hydatid cyst of the right frontal lobe. Revta Asoc Méd Argent. 1929;1929(4):209–17. [in Spanish]
7. Altinors N, Bavbek M, Caner HH, Erdogan B. Central nervous system hydatidosis in Turkey: A cooperative study and literature survey analysis of 458 cases. J Neurosurg. 2000;93(1):1–8.
8. Rumana M, Mahadevan A, Nayil Khurshid M, et al. Cestode parasitic infestation: intracranial and spinal hydatid disease – a clinicopathological study of 29 cases from South India. Clin Neuropathol. 2006;25(2):98–104.
9. Sardi I, Sanzo M, Buccoliero AM, et al. Intracerebral atypical presentation of echinococcosis in a child. Pediatr Neurosurg. 2008;44(4):350–52.

10. Lunardi P, Missori P, Di Lorenzo N, Fortuna A. Cerebral hydatidosis in childhood: A retrospective survey with emphasis on long-term follow-up. *Neurosurgery*. 1991;29(4):515–17. discussion 517–18.

11. Ciurea AV, Fountas KN, Coman TC, et al. Long-term surgical outcome in patients with intracranial hydatid cyst. *Acta Neurochir (Wien)* 2006;148(4):421–26. [

12. Luo K, Luo DH, Zhang TR, Wen H. Primary intracranial and spinal hydatidosis: A retrospective study of 21 cases. *Pathog Glob Health*. 2013;107(2):47–51. [

13. Okur A, Ogul H, Sengul G, et al. Magnetic resonance spectroscopy and magnetic resonance imaging findings of the intracerebral alveolar echinococcosis. *J Craniofac Surg*. 2014;25(4):1352–53.

14. Amin OS. Multiple cerebral hydatid cysts: Have the previous operations contributed to their formation? *BMJ Case Rep*. 2012;2012 pii: bcr2012007240. [

15. Yuceer N, Guven MB, Yilmaz H. Multiple hydatid cysts of the brain: A case report and review of the literature. *Neurosurg Rev*. 1998;21(2–3):181–84.]

16. Ersahin Y, Mutluer S, Guzelbag E. Intracranial hydatid cysts in children. *Neurosurgery*. 1993;33(2):219–24. discussion 224–25.]

17. Debourgogne A, Goehringer F, Umhang G, et al. Primary cerebral alveolar echinococcosis: Mycology to the rescue. *J Clin Microbiol*. 2014;52(2):692–94. [

18. Tuzun Y, Kadioglu HH, Izci Y, et al. The clinical, radiological and surgical aspects of cerebral hydatid cysts in children. *Pediatr Neurosurg*. 2004;40(4):155–60. [

19. Guzel A, Tatli M, Maciaczyk J, Altinors N. Primary cerebral intraventricular hydatid cyst: A case report and review of the literature. *J Child Neurol*. 2008;23(5):585–88. [

20. Diaz de Durana MD, Lopez A, Fraj J. Anaphylaxis and cerebral hydatidic disease. *Ann Intern Med.* 1997;126(9):745. [

21. Umerani MS, Abbas A, Sharif S. Intra cranial hydatid cyst: A case report of total cyst extirpation and review of surgical technique. *J Neurosci Rural Pract.* 2013;4(Suppl 1):S125–28. []

22. Onal C, Unal F, Barlas O, et al. Long-term follow-up and results of thirty pediatric intracranial hydatid cysts: half a century of experience in the Department of Neurosurgery of the School of Medicine at the University of Istanbul (1952–2001) *Pediatr Neurosurg.* 2001;35(2):72–81.

23. Tuzun Y, Solmaz I, Sengul G, Izcı Y. The complications of cerebral hydatid cyst surgery in children. *Childs Nerv Syst.* 2010;26(1):47–51.

24. Horton RJ. Albendazole in treatment of human cystic echinococcosis: 12 years of experience. *Acta Trop.* 1997;64(1–2):79–93.

25. Junghanss T, da Silva AM, Horton J, et al. Clinical management of cystic echinococcosis: State of the art, problems, and perspectives. *Am J Trop Med Hyg.* 2008;79(3):301–11.

26. Duishanbai S, Jiafu D, Guo H, et al. Intracranial hydatid cyst in children: Report of 30 cases. *Childs Nerv Syst.* 2010;26(6):821–

عملية عاجلة لكيس مائي عملاق في الدماغ : حالة مسجلة

د. امجد حسن صاحب/ اختصاص جراحة الجملة العصبية/ مستشفى الامام
الحسين التعليمي/ ذي قار

د. فراس عبد الله نوري / اختصاص اشعه تشخيصية/ كلية الطب – جامعة
ذي قار

الخلاصة

تقرير عن تجربتنا مع حالة نادرة من الاكياس المائية في الدماغ و التي كانت تتطلب جراحة عاجلة بسبب ارتفاع الضغط داخل الجمجمة والذي يهدد حياة المريض. وتمت ازالة الكيس بشكل تام و ككتلة واحدة، وبعدها استأنف المريض نشاطه اليومي دون عجز عصبي. وعادة ما يتم علاج الكيس المائي في الدماغ من خلال عدة عمليات مجدولة ، لكن في بعض الحالات قد يسبب حالة طارئة لدى المريض المعني. جراحة تخفيف ضغط الدماغ الفوري عن طريق ازالة الكيس بعد الحد الأدنى من التحريات السريرية ينصح في أي عمليات